

American Heart Association

Pediatric Advanced Life Support

Written Precourse Self-Assessment

December 2006

PALS Written 2006 Precourse Self-Assessment

ECG Rhythm Identification

The PALS self-assessment on ECG rhythm identification is designed to test your ability to identify rhythms you may encounter as a PALS provider. The rhythms listed below in **boldface** type are the core PALS rhythms that you should be able to identify during the PALS Provider Course teaching and testing stations. If you have difficulty with pediatric ECG rhythm identification, we strongly suggest that you spend additional time reviewing basic pediatric arrhythmias before the PALS Provider Course. Sources of information about pediatric ECG rhythm identification include the ECG Basics section of the student CD, the *PALS Course Guide*, and the *PALS Provider Manual*.

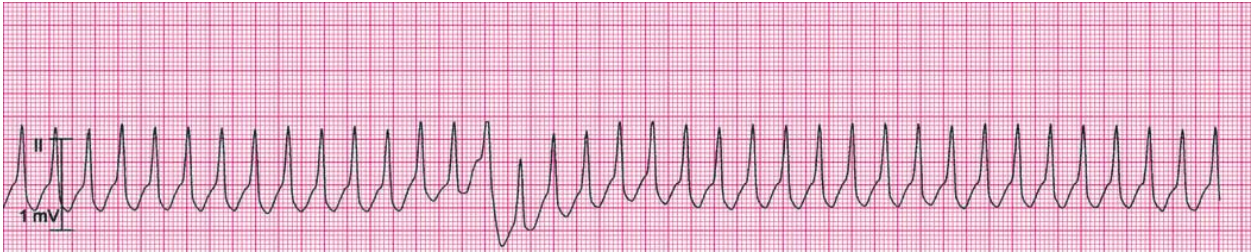
The rhythm identification self-assessment has 13 multiple choice questions. Questions 1 to 8 cover the core PALS rhythms (see rhythms in **boldface** below). Questions 9 to 13 contain advanced material that you don't have to know before the PALS course but that may be useful to your clinical practice. For all questions select the single best answer (ie, rhythm) from the list of 14 rhythms (A to M) below. A question may have more than one correct answer. Annotated answers that explain both correct and incorrect answer selections are located at the end of the self-assessments. The ECG Basics sections of the student CD and other sources of information are given in the annotations. There are 3 self-assessment tests: ECG Rhythm Identification, Pharmacology, and Practical Application.

Pediatric Rhythms (core PALS rhythms A to H; non-core rhythms I to M):

- A. **Normal sinus rhythm**
- B. **Sinus tachycardia**
- C. **Sinus bradycardia**
- D. **Supraventricular tachycardia (SVT)**
- E. **Wide-complex tachycardia; presumed ventricular tachycardia (monomorphic)**
- F. **Ventricular fibrillation (VF)**
- G. **Asystole**
- H. **Pulseless electrical activity (PEA)**
- I. SVT converting to sinus rhythm with adenosine administration
- J. Wide-complex tachycardia (in a child with known aberrant intraventricular conduction; this is SVT with aberrant conduction)
- K. First-degree AV block
- L. Torsades de pointes (polymorphic ventricular tachycardia)
- M. VF converted to organized rhythm after successful shock delivery (defibrillation)

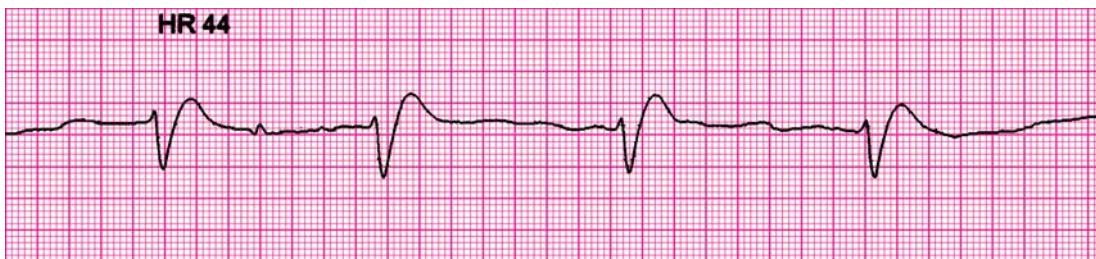Rhythms 1 to 8: Core PALS Rhythms (**select single best answer from rhythms A to H**)

Rhythm 1 (clinical clue: heart rate 214/min)



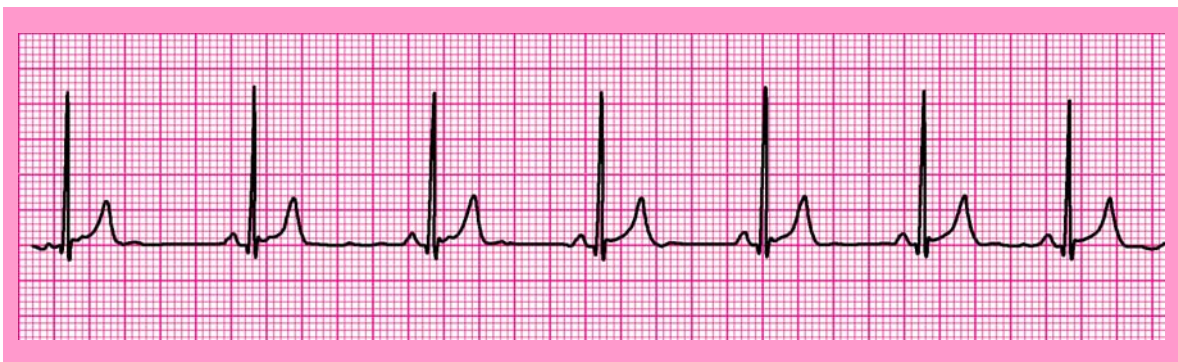For further information: see the PALS Provider Manual Chapter 6: Recognition and Management of Bradyarrhythmias and Tachyarrhythmias and Chapter 7: Recognition and Management of Cardiac Arrest.

Rhythm 2 (clinical clues: heart rate 44/min; no detectable pulses)



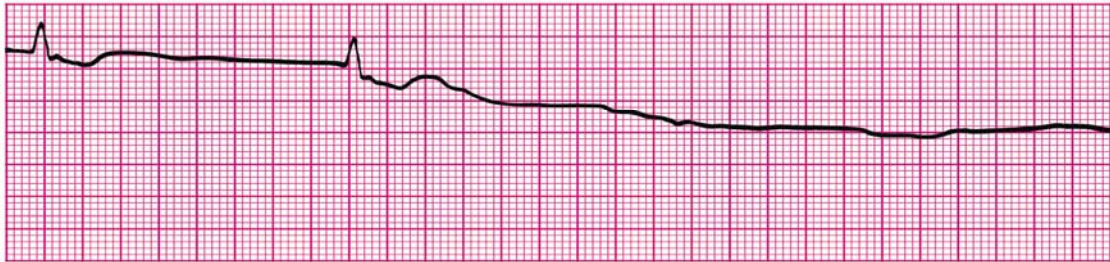
For further information: see the PALS Provider Manual Chapter 6: Recognition and Management of Bradyarrhythmias and Tachyarrhythmias.

Rhythm 3 (clinical clues: age 8 years; heart rate 50/min)



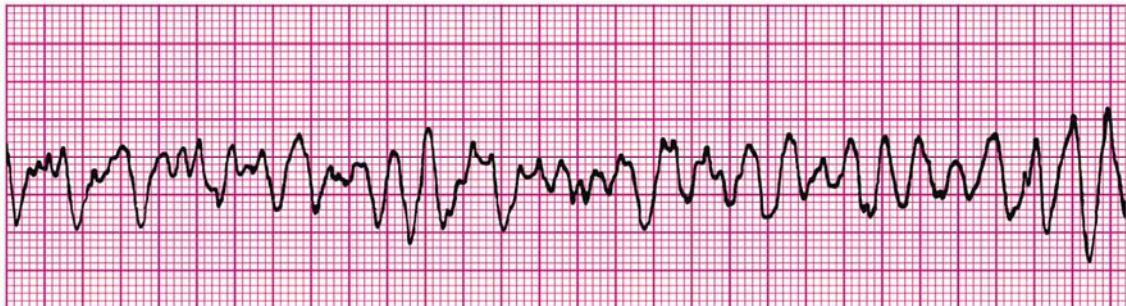For further information: see the PALS Provider Manual Chapter 6: Recognition and Management of Bradyarrhythmias and Tachyarrhythmias.

Rhythm 4 (clinical clue: no detectable pulses)



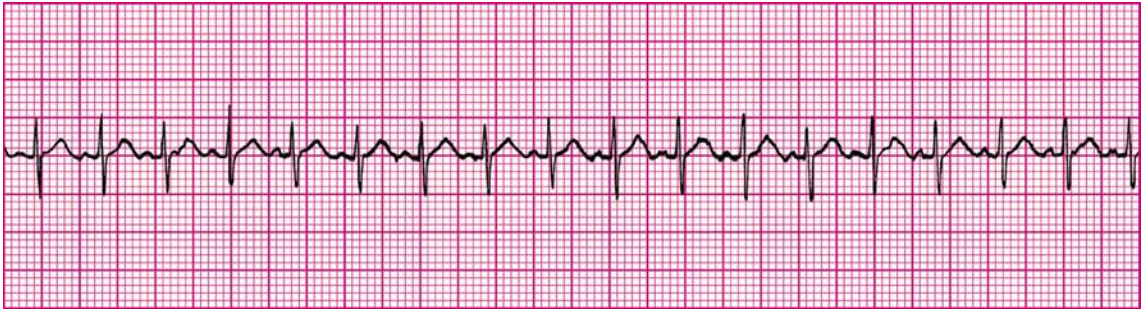
For further information: see the PALS Provider Manual Chapter 7: Recognition and Management of Cardiac Arrest.

Rhythm 5 (clinical clue: no consistent heart rate detected; no detectable pulses)



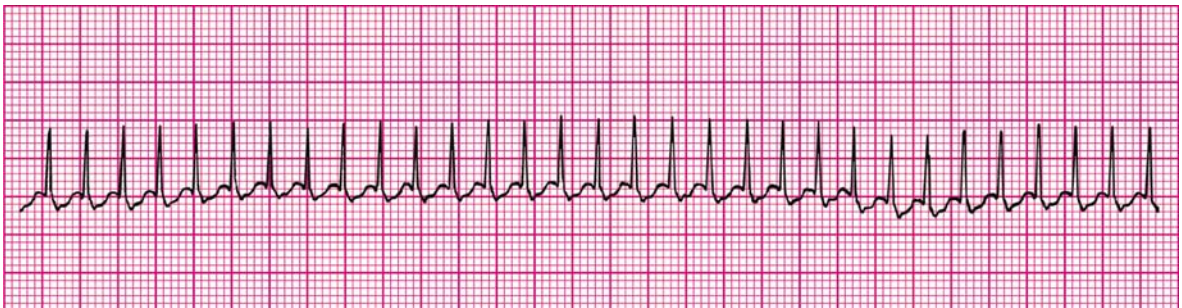
For further information: see the PALS Provider Manual Chapter 7: Recognition and Management of Cardiac Arrest.

Rhythm 6 (clinical clues: age 3 years; heart rate 188/min)



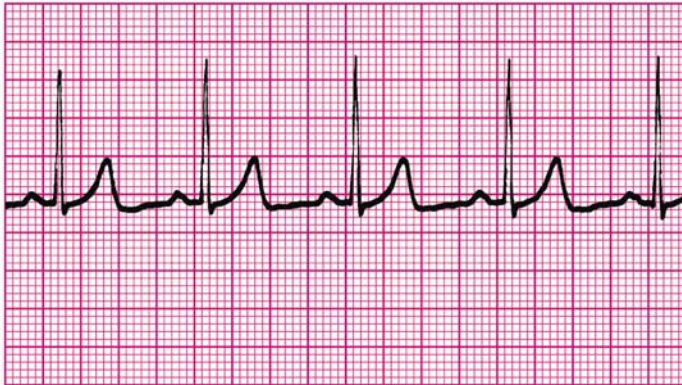
For further information: see the PALS Provider Manual Chapter 6: Recognition and Management of Bradyarrhythmias and Tachyarrhythmias.

Rhythm 7 (clinical clue: heart rate 300/min)



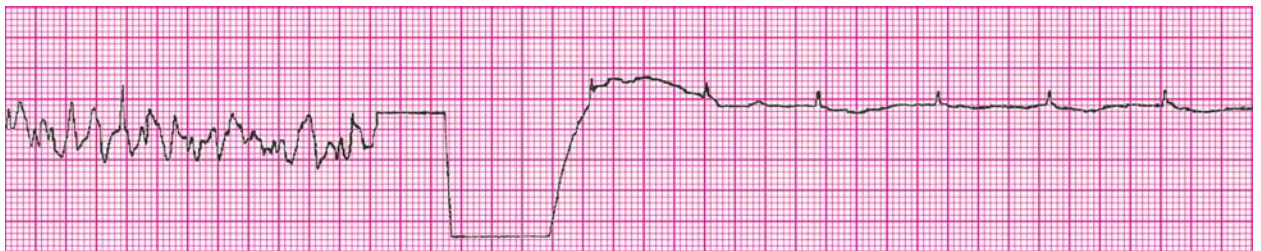For further information: see the PALS Provider Manual Chapter 6: Recognition and Management of Bradyarrhythmias and Tachyarrhythmias.

Rhythm 8 (clinical clues: age 8 years; heart rate 75/min)



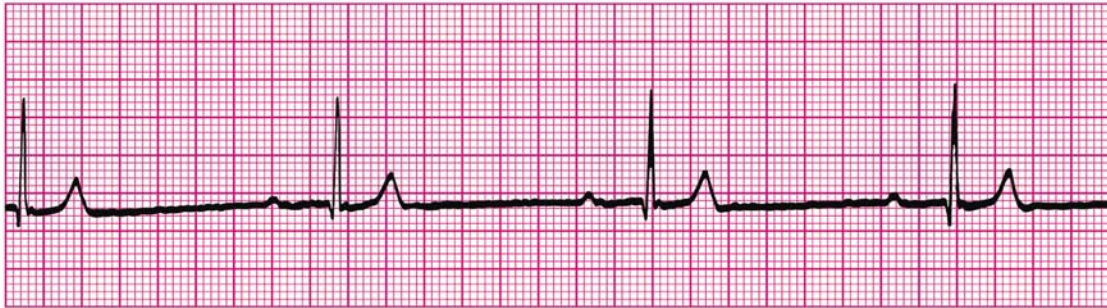
Rhythms 9 to 13: Non-core Rhythms

Rhythm 9 (clinical clue: initial rhythm associated with no detectable pulses)



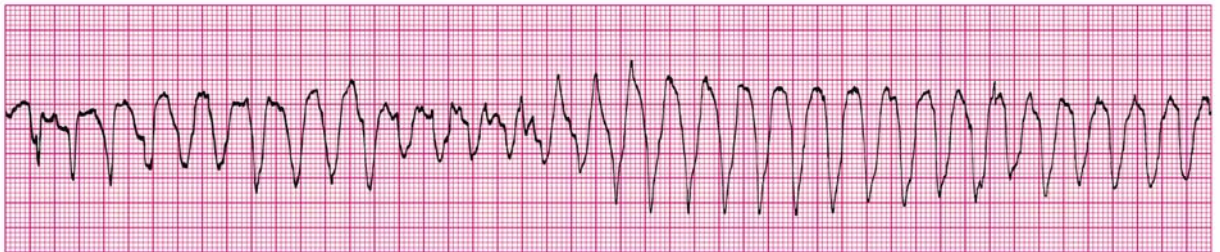
For further information: see PALS Provider Manual Chapter 7: Recognition and Management of Cardiac Arrest

Rhythm 10 (clinical clues: age 9 months; heart rate 38/min)



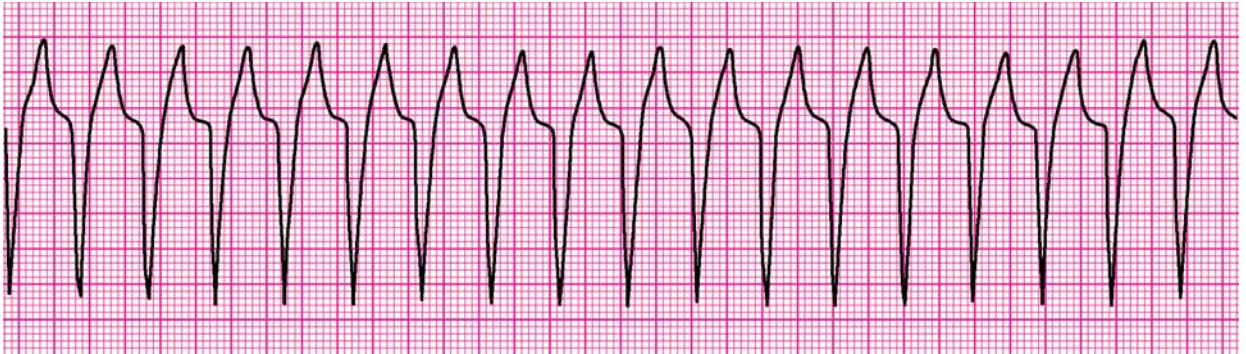
For further information: see the PALS Provider Manual Chapter 6: Recognition and Management of Bradyarrhythmias and Tachyarrhythmias.

Rhythm 11 (clinical clues: heart rate 200/min; no detectable pulses)



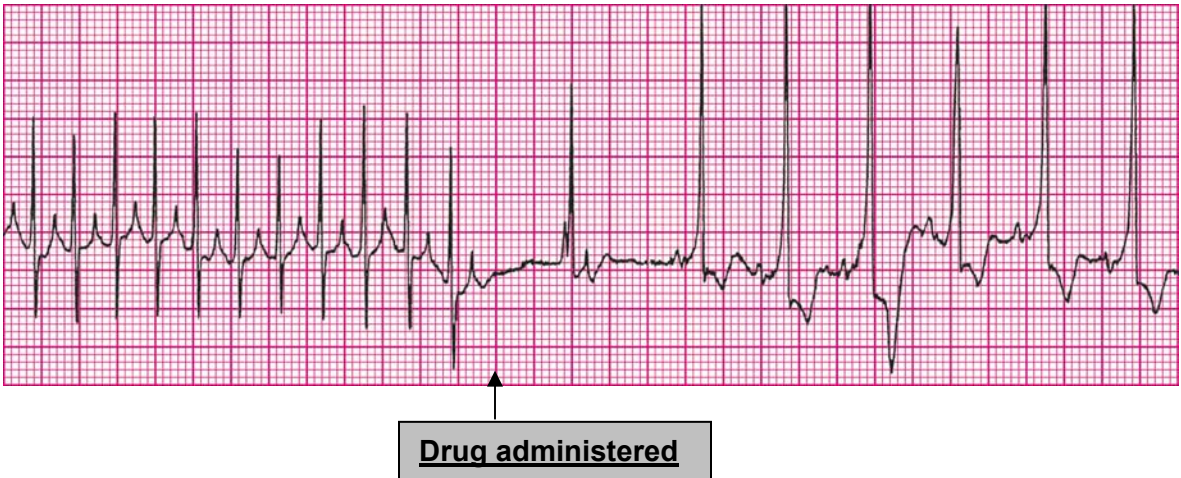
For further information: see the PALS Provider Manual Chapter 6: Recognition and Management of Bradyarrhythmias and Tachyarrhythmias and Chapter 7: Recognition and Management of Cardiac Arrest.

Rhythm 12 (clinical clue: heart rate 150/min)



For further information: see the PALS Provider Manual Chapter 6: Recognition and Management of Bradyarrhythmias and Tachyarrhythmias.

Rhythm 13 (clinical clue: initial rhythm associated with heart rate 300/min)



For further information: see the PALS Provider Manual Chapter 6: Recognition and Management of Bradyarrhythmias and Tachyarrhythmias.

PALS Written 2006 Precourse Self-Assessment

Pharmacology

The PALS Pharmacology Self-Assessment is designed to test your knowledge of core drugs that will be used in the PALS Provider Course. This drug knowledge includes the indications, contraindications, and methods for administration of these agents. This exercise tests your ability to correctly use these drugs in scenarios similar to those you are likely to encounter in the PALS Provider Course teaching and testing stations. The stations are designed to simulate the knowledge you will need to care for seriously ill or injured children.

If this self-assessment shows that your knowledge of the pharmacology and indications for these drugs is deficient, we strongly suggest that you spend additional time reviewing basic resuscitation drug pharmacology before taking a PALS course. Sources of PALS drug information include the student CD, the *PALS Course Guide*, the *PALS Provider Manual*, and the *Handbook of Emergency Cardiovascular Care* (ECC Handbook).

The Pharmacology self-assessment consists of 11 multiple choice questions. Select the single best answer. Annotated answers that explain both correct and incorrect answer selections are located at the end of the self-assessments. The Pharmacology section of the student CD and other appropriate sources of further information are provided in the annotations. There are 3 self-assessment tests: ECG Rhythm Identification, Pharmacology, and Practical Application.

1. You are called to help resuscitate an infant with severe symptomatic bradycardia associated with respiratory distress. The bradycardia persists despite establishment of an effective airway, oxygenation, and ventilation. There is no heart block present. Which of the following is the *first drug* you should administer?
- A. Atropine
 - B. Dopamine
 - C. Adenosine
 - D. Epinephrine

For further information: see the PALS Provider Manual Chapter 6: Recognition and Management of Bradyarrhythmias and Tachyarrhythmias, Chapter 9: Pharmacology, and the PALS Course Guide Part 10: Pharmacology.

2. Which of the following statements about the effects of epinephrine during attempted resuscitation is true?
- A. Epinephrine decreases peripheral vascular resistance and reduces myocardial afterload so that ventricular contractions are more effective
 - B. Epinephrine improves coronary artery perfusion pressure and stimulates spontaneous contractions when asystole is present
 - C. Epinephrine is contraindicated in ventricular fibrillation because it increases myocardial irritability
 - D. Epinephrine decreases myocardial oxygen consumption

For further information: see the PALS Provider Manual Chapter 9: Pharmacology, and the PALS Course Guide Part 10: Pharmacology.

3. General assessment of a 2-year-old female reveals her to be alert with mild breathing difficulty during inspiration and pale skin color. On primary assessment, she makes high-pitched inspiratory sounds (mild stridor) when agitated; otherwise her breathing is quiet. Her SpO₂ is 92% in room air, and she has mild inspiratory intercostal retractions. Lung auscultation reveals transmitted upper airway sounds with adequate distal breath sounds bilaterally. Which of the following is the most appropriate initial therapy intervention for this child?
- A. Perform immediate endotracheal intubation
 - B. Administer an IV dose of dexamethasone
 - C. Nebulize 2.5 mg of albuterol
 - D. Administer humidified supplementary oxygen as tolerated and continue evaluation

For further information: see the PALS Provider Manual Chapter 2: Recognition of Respiratory Distress and Failure, Chapter 3: Management of Respiratory Distress and Failure, Chapter 9: Pharmacology, and the PALS Course Guide Part 10: Pharmacology.

4. Which of the following most reliably delivers a high (90% or greater) concentration of inspired oxygen in a toddler or older child?

- A. Nasal cannula with 4 L/min oxygen flow
 - B. Simple oxygen mask with 15 L/min oxygen flow
 - C. Nonrebreathing face mask with 12 L/min oxygen flow
 - D. Face tent with 15 L/min oxygen flow
-

5. Which of the following statements about endotracheal drug administration is true?

- A. Endotracheal drug administration is the preferred route of drug administration during resuscitation because it results in predictable drug levels and drug effects
- B. Endotracheal doses of resuscitation drugs in children have been well established and are supported by evidence from clinical trials
- C. Intravenous drug doses for resuscitation drugs should be used whether you give the drugs by the IV, intraosseous (IO), or the endotracheal route
- D. Endotracheal drug administration is the least desirable route of administration because this route results in unpredictable drug levels and effects

For further information: see the PALS Provider Manual Chapter 7: Recognition and Management of Cardiac Arrest, Chapter 9: Pharmacology, and the PALS Course Guide Part 10: Pharmacology.

6. Which of the following statements most accurately reflects the PALS recommendations for the use of magnesium sulfate in the treatment of cardiac arrest?

- A. Magnesium sulfate is indicated for VF refractory to repeated shocks and amiodarone or lidocaine
- B. Routine use of magnesium sulfate is indicated for shock-refractory monomorphic VT
- C. Magnesium sulfate is indicated for torsades de pointes or suspected hypomagnesemia
- D. Magnesium sulfate is contraindicated in VT associated with an abnormal QT interval during the preceding sinus rhythm

For further information: see the PALS Provider Manual Chapter 6: Recognition and Management of Bradyarrhythmias and Tachyarrhythmias, Chapter 7: Recognition and Management of Cardiac Arrest, Chapter 9: Pharmacology, and the PALS Course Guide Part 10: Pharmacology.

7. You enter a room to perform a general assessment of a previously stable 10-year-old male and find him unresponsive and apneic. A code is called and bag-mask ventilation is performed with 100% oxygen. The cardiac monitor shows a wide-complex tachycardia. The boy has no detectable pulses. You deliver an unsynchronized shock with 2 J/kg. The rhythm check after 2 minutes of CPR reveals VF. You then deliver a shock of 4 J/kg and resume immediate CPR beginning with compressions. A team member had established IO access, so you give a dose of epinephrine, 0.01 mg/kg (0.1 mL/kg of 1:10,000 dilution) IO when CPR is restarted after the second shock. At the next rhythm check, persistent VF is present. You administer a 4 J/kg shock and resume CPR. Based on the PALS Pulseless Arrest Algorithm, what are the next drug and dose to administer when CPR is restarted?
- A. Epinephrine 0.1 mg/kg (0.1 mL/kg of 1:1,000 dilution) IO
 - B. Atropine 0.02 mg/kg IO
 - C. Amiodarone 5 mg/kg IO
 - D. Magnesium sulfate 25 to 50 mg/kg IO

For further information: see the PALS Provider Manual Chapter 7: Recognition and Management of Cardiac Arrest, Chapter 9: Pharmacology, and the PALS Course Guide Part 10: Pharmacology.

8. Parents of a 1-year-old female phoned the Emergency Response System when they picked up their daughter from the baby-sitter. Paramedics perform a general assessment revealing an obtunded infant with irregular breathing, bruises over the abdomen, abdominal distention, and cyanosis. Assisted bag-mask ventilation with 100% oxygen is initiated. On primary assessment heart rate is 36/min, peripheral pulses cannot be palpated, and central pulses are barely palpable. Cardiac monitor shows sinus bradycardia. Chest compressions are started with a 15:2 compression-to-ventilation ratio. In the emergency department the infant is intubated and ventilated with 100% oxygen, and IV access is established. The heart rate is now up to 150/min but there are weak central pulses and no distal pulses. Systolic blood pressure is 74 mm Hg. Of the following, which would be most useful in management of this infant?
- A. Epinephrine 0.01 mg/kg (0.1 mL/kg of 1:10,000 dilution) IV
 - B. Rapid bolus of 20 mL/kg of isotonic fluid
 - C. Atropine 0.02 mg/kg IV
 - D. Synchronized cardioversion

For further information: see the PALS Provider Manual Chapter 6: Recognition and Management of Bradyarrhythmias and Tachyarrhythmias, Chapter 9: Pharmacology, and the PALS Course Guide Part 10: Pharmacology.

9. Which of the following statements about calcium is true?

- A. Routine administration of calcium is not indicated during cardiac arrest.
- B. The recommended dose is 1 to 2 mg/kg of calcium chloride
- C. Calcium chloride 10% has the same bioavailability of elemental calcium as calcium gluconate in critically ill children
- D. Indications for administration of calcium include hypercalcemia, hypokalemia, and hypomagnesemia

For further information: see the PALS Provider Manual Chapter 9: Pharmacology, and the PALS Course Guide Part 10: Pharmacology.

10. An infant with a history of vomiting and diarrhea arrives by ambulance. During your primary assessment the infant responds only to painful stimulation. The upper airway is patent, the respiratory rate is 40/min with good bilateral breath sounds, and 100% oxygen is being administered. The infant has cool extremities, weak pulses, and a capillary refill time of more than 5 seconds. The infant's blood pressure is 85/65 mm Hg, and glucose concentration (measured by bedside test) is 30 mg/dL. Which of the following is the most appropriate treatment to provide for this infant?

- A. Establish IV or IO access and administer 20 mL/kg D₅0.45% sodium chloride bolus over 15 minutes
- B. Establish IV or IO access and administer 20 mL/kg Lactated Ringer's solution over 60 minutes
- C. Perform endotracheal intubation and administer epinephrine 0.1 mg/kg 1:1,000 via the endotracheal tube
- D. Establish IV or IO access, administer 20 mL/kg isotonic crystalloid over 10 to 20 minutes, and simultaneously administer D₂₅W 2 to 4 mL/kg in a separate infusion

For further information: see the PALS Provider Manual Chapter 4: Recognition of Shock, Chapter 5: Management of Shock, Chapter 9: Pharmacology, and the PALS Course Guide Part 10: Pharmacology.

11. General assessment of a 9-year-old male with increased work of breathing. reveals the boy to be agitated and leaning forward on the bed with obvious respiratory distress. You administer 100% oxygen by nonrebreathing mask. The patient is speaking in short phrases and tells you that he has asthma but does not carry an inhaler. He has nasal flaring, severe suprasternal and intercostal retractions, and decreased air movement with prolonged expiratory time and wheezing. His SpO₂ is 92% (on nonrebreathing mask). What is the next medical therapy to provide to this patient?
- A. Adenosine 0.1 mg/kg
 - B. Amiodarone 5 mg/kg IV/IO
 - C. Albuterol by nebulization
 - D. Procainamide 15 mg/kg IV/IO

For further information: see the PALS Provider Manual Chapter 3: Recognition of Respiratory Distress and Failure, Chapter 4: Management of Respiratory Distress and Failure, Chapter 9: Pharmacology, and the PALS Course Guide Part 10: Pharmacology.

PALS Written 2006 Precourse Self-Assessment

Practical Application

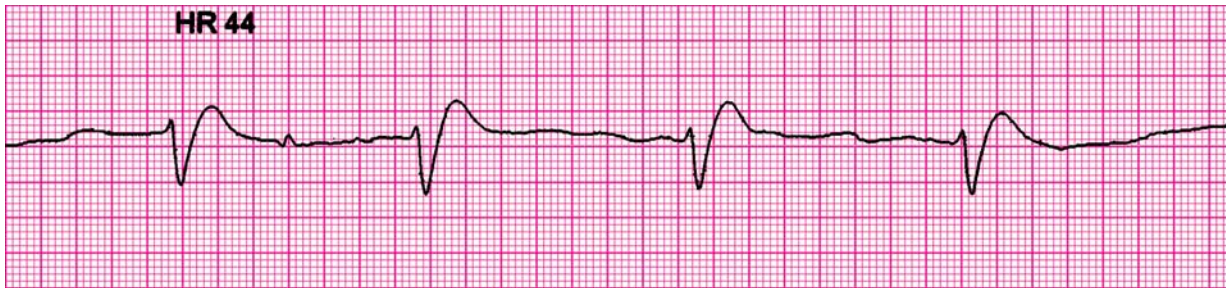
The PALS practical application self-assessment is designed to test your knowledge of appropriate treatment selections based on pediatric assessment information provided in case scenarios. This exercise specifically evaluates your ability to identify core PALS rhythms (if presented), knowledge of core drugs, knowledge of the PALS flowcharts and algorithms for respiratory distress/respiratory failure and shock, and knowledge of the PALS algorithms for rhythm disturbances.

In previous self-assessments you practiced your pediatric rhythm identification skills (ECG Rhythm Identification) and your knowledge of core drugs (Pharmacology). Ideally you should demonstrate proficiency in these subjects before continuing with this test.

If you have difficulty with the practical application questions, we strongly suggest that you review the core the PALS rhythms, core drug information, the PALS flowcharts and algorithms for respiratory distress/failure and shock, and the PALS algorithms for rhythm disturbances. Sources of this information include the student CD (see Practice Cases), the *PALS Course Guide*, the *PALS Provider Manual*, and the *Handbook of Emergency Cardiovascular Care*.

This self-assessment consists of 19 multiple choice questions. Select the single best answer. Annotated answers that explain both correct and incorrect answer selections are located at the end of the self-assessments. The ECG Basics and Pharmacology sections of the student CD and other appropriate sources of information are in the annotations. There are 3 self-assessment tests: ECG Rhythm Identification, Pharmacology, and Practical Application.

1. An 8-month-old male is brought to the emergency department (ED) for evaluation of severe diarrhea and dehydration. In the ED the child becomes unresponsive and pulseless. You shout for help and start CPR at a compression rate of 100/min and a compression-to-ventilation ratio of 30:2. Another provider arrives, at which point you switch to 2-rescuer CPR with a compression-to-ventilation ratio of 15:2. The cardiac monitor shows the following rhythm:

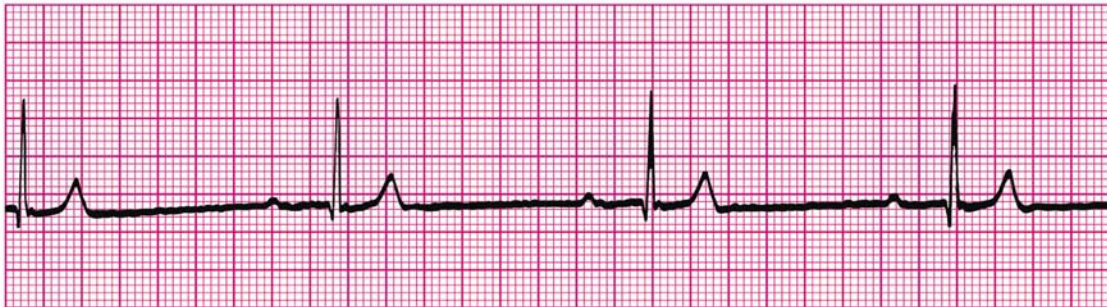

The infant is intubated and ventilated with 100% oxygen. An IO line is rapidly established and a dose of epinephrine is given. Of the following choices for management, which would be most appropriate to give next?

- A. Defibrillation 2 J/kg
- B. Normal saline 20 mL/kg IV rapidly
- C. High-dose epinephrine, 0.1 mg/kg (0.1 mL/kg of 1:1,000 dilution), IO
- D. Amiodarone 5 mg/kg IO

For further information: see the PALS Provider Manual Chapter 7: Recognition and Management of Cardiac Arrest, Chapter 9: Pharmacology, the PALS Course Guide Part 6: Cardiac Arrest, and Part 10: Pharmacology.

2. General assessment of a 10-month-old male in the emergency department reveals a lethargic pale infant with slow respirations. You begin assisted ventilation with a bag-mask device using 100% oxygen. On primary assessment heart rate is 38/min, central pulses are weak but distal pulses cannot be palpated, blood pressure is 60/40 mm Hg, and capillary refill is 4 seconds. During your assessment a colleague places the child on a cardiac monitor and you observe the following rhythm:

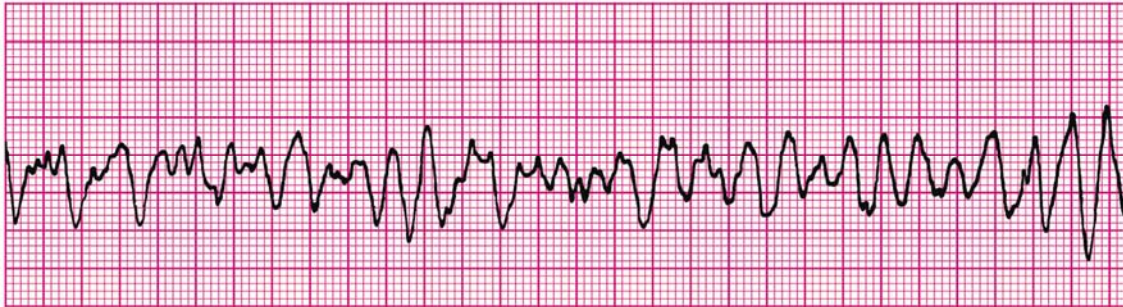


The rhythm remains unchanged despite ventilation with 100% oxygen. What are your next management steps?

- A. Administer adenosine 0.1 mg/kg rapid IV/IO and prepare for synchronized cardioversion
- B. Start chest compressions and give epinephrine 0.1 mg/kg (0.1 mL/kg of 1:1,000 dilution) IV/IO
- C. Start chest compressions and give epinephrine 0.01 mg/kg mL/kg of 1:10,000 dilution) IV/IO
- D. Administer 20 mL/kg isotonic crystalloid and epinephrine 0.1 mg/kg mL/kg of 1:10,000 dilution) IV/IO

For further information: see the PALS Provider Manual Chapter 6: Recognition and Management of Bradyarrhythmias and Tachyarrhythmias, Chapter 9: Pharmacology, the PALS Course Guide Part 7: Bradyarrhythmias and Tachyarrhythmias and Part 10: Pharmacology.

3. A 3-year-old unresponsive, apneic child is brought to the emergency department. EMS personnel report that the child became unresponsive as they arrived at the hospital. The child is receiving CPR, including bag-mask ventilation with 100% oxygen and chest compressions at a rate of 100/min. Compressions and ventilations are being coordinated at a ratio of 15:2. You confirm that apnea is present and that ventilation is producing bilateral breath sounds and chest expansion while a colleague confirms absent pulses. Cardiac monitor shows the following rhythm:

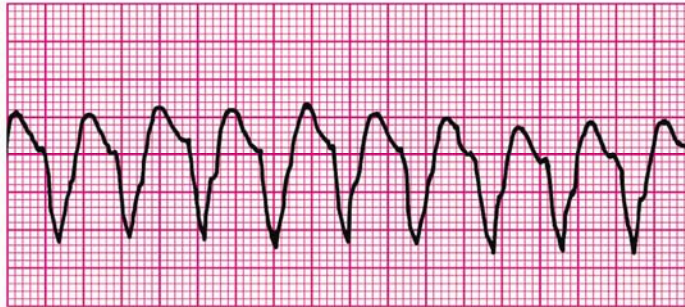


A biphasic manual defibrillator is present. You quickly use the crown-heel length of the child on a length-based, color-coded resuscitation tape to estimate the approximate weight as 15 kg. Which of the following therapies is most appropriate for this child at this time?

- A. Establish IV/IO access and administer amiodarone 5 mg/kg IV/IO
- B. Establish IV/IO access and administer lidocaine 1 mg/kg IV/IO
- C. Attempt defibrillation at 30 J, then resume CPR beginning with compressions
- D. Establish IV/IO access and administer epinephrine 0.01 mg/kg (0.1 mL/kg of 1:10,000 dilution) IV/IO

For further information: see the PALS Provider Manual Chapter 7: Recognition and Management of Cardiac Arrest, Chapter 9: Pharmacology, the PALS Course Guide Part 6: Cardiac Arrest, and Part 10: Pharmacology.

4. General assessment of a 10-year-old male shows him to be unresponsive. You shout for help, check breathing, find he is apneic, and give 2 breaths. After finding that he is pulseless, you begin cycles of compressions and ventilations with a compression rate of 100/min and compression-to-ventilation ratio of 30:2. A colleague arrives and places the child on a cardiac monitor, revealing the following rhythm:

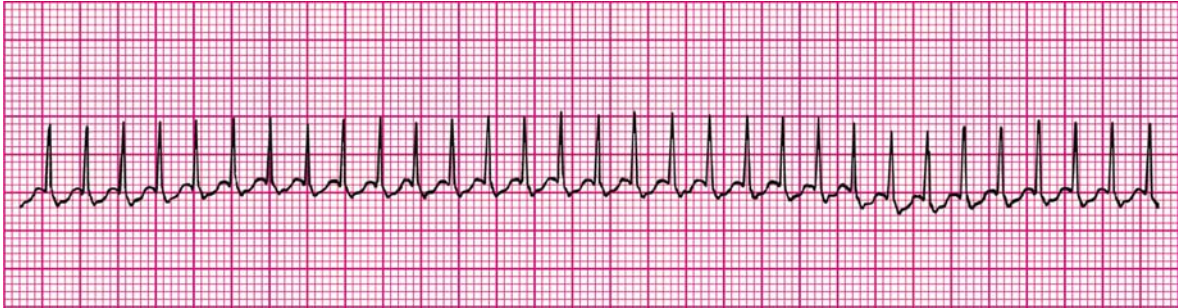


The two of you attempt defibrillation at 2 J/kg and give 2 minutes of CPR. The rhythm persists at the second rhythm check, at which point you attempt defibrillation using 4 J/kg. A third colleague establishes IO access and administers one dose of epinephrine 0.01 mg/kg (0.1 mL/kg of 1:10,000 dilution) during the compressions following the second shock. If VF or pulseless VT persists after 2 minutes of CPR, what is the *next* drug/dose to administer?

- A. Epinephrine 0.1 mg/kg (0.1 mL/kg of 1:1,000 dilution) IV
- B. Adenosine 0.1 mg/kg IV
- C. Amiodarone 5 mg/kg IV
- D. Atropine 0.02 mg/kg IV

For further information: see the PALS Provider Manual Chapter 7: Recognition and Management of Cardiac Arrest, Chapter 9: Pharmacology, the PALS Course Guide Part 6: Cardiac Arrest, and Part 10: Pharmacology.

5. A 1-year-old male is brought to the emergency department for evaluation of poor feeding, fussiness, and sweating. On general assessment he is lethargic but arousable and has labored breathing and a dusky color. Primary assessment reveals a respiratory rate of 68/min, heart rate 300/min that does not vary with activity or sleep, blood pressure 70/45 mm Hg, weak brachial pulses and absent radial pulses, capillary refill 6 seconds, SpO₂ 85% in room air, and good bilateral breath sounds. You administer high-flow oxygen and place the child on a cardiac monitor. You see the following rhythm with little beat-to-beat variability of the heart rate:

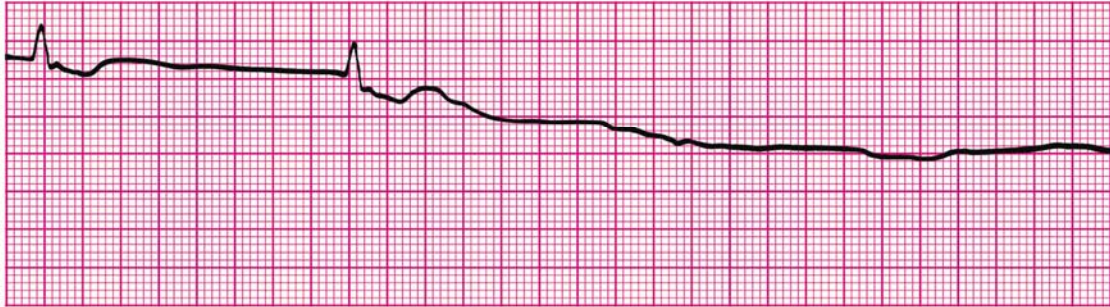


Secondary assessment reveals no history of congenital heart disease. IV access has been established. Which of the following therapies is most appropriate for this infant?

- A. Make an appointment with a pediatric cardiologist for later in the week
- B. Adenosine 0.1 mg/kg IV rapidly; if adenosine is not immediately available, perform synchronized cardioversion
- C. Perform immediate defibrillation without waiting for IV access
- D. Establish IV access and administer a fluid bolus of 20 mL/kg isotonic crystalloid

For further information: see the PALS Provider Manual Chapter 6: Recognition and Management of Bradyarrhythmias and Tachyarrhythmias, and the PALS Course Guide Part 7: Bradyarrhythmias and Tachyarrhythmias.

6. A child becomes unresponsive in the emergency department and is not breathing. You provide ventilation with 100% oxygen. You are uncertain if a faint pulse is present with the following rhythm:



What is your *next* action?

- A. Begin high-quality chest compressions with ventilations
- B. Order transcutaneous pacing
- C. Start an IV and give atropine 0.01 mg/kg IV
- D. Start an IV and give epinephrine 0.01 mg/kg IV (0.1 mL/kg of 1:10,000 dilution)

For further information: see the PALS Provider Manual Chapter 7: Recognition and Management of Cardiac Arrest, Chapter 9: Pharmacology, the PALS Course Guide Part 6: Cardiac Arrest, and Part 10: Pharmacology.

7. You are preparing to use a manual defibrillator and paddles in the pediatric setting. When would it be most appropriate to use the smaller “pediatric” sized paddles for shock delivery?

- A. To attempt synchronized cardioversion but not defibrillation
- B. If the patient weighs less than approximately 25 kg or is less than 8 years of age
- C. If the patient weighs less than approximately 10 kg or is less than 1 year of age
- D. Whenever you can compress the victim's chest using only the heel of one hand

For further information: see the PALS Provider Manual Chapter 7: Recognition and Management of Cardiac Arrest, Chapter 9: Pharmacology, and the PALS Course Guide Part 6: Cardiac Arrest.

8. **A 7-year-old boy is found unresponsive, apneic, and pulseless. CPR is ongoing. The child is intubated and vascular access is established. The ECG monitor reveals an organized rhythm, but a pulse check reveals no palpable pulses. Effective ventilations and compressions are resumed, and an initial IV dose of epinephrine is administered. Which of the following therapies should you perform next?**
- A. Attempt to identify and treat reversible causes (using the H's and T's as a memory aid)
 - B. Attempt defibrillation at 4 J/kg
 - C. Administer epinephrine 0.1 mg/kg IV (0.1 mL/kg of 1:1,000 dilution)
 - D. Administer synchronized cardioversion at 1 J/kg

For further information: see the PALS Provider Manual Chapter 7: Recognition and Management of Cardiac Arrest, Chapter 9: Pharmacology, and the PALS Course Guide Part 6: Cardiac Arrest.

9. **You are evaluating an irritable 6-year-old girl with mottled color. On primary assessment she is febrile (temperature 40°C [104°F]), and her extremities are cold (despite a warm ambient temperature in the room) with capillary refill of 5 seconds. Distal pulses are absent and central pulses are weak. Heart rate is 180/min, respiratory rate is 45/min, and blood pressure is 98/56 mm Hg. Which of the following most accurately describes the categorization of this child's condition using the terminology taught in the PALS Provider Course?**
- A. Hypotensive shock associated with inadequate tissue perfusion
 - B. Hypotensive shock associated with inadequate tissue perfusion and significant hypotension
 - C. Compensated shock requiring no intervention
 - D. Compensated shock associated with tachycardia and inadequate tissue perfusion

For further information: see the PALS Provider Manual Chapter 4: Recognition of Shock, Chapter 5: Management of Shock, and the PALS Course Guide Part 9: Shock.

10. An 8-year-old child was struck by a car. He arrives in the emergency department alert, anxious, and in respiratory distress. His cervical spine is immobilized, and he is receiving a 10 L/min flow of 100% oxygen by nonrebreathing face mask. Primary assessment reveals respiratory rate 60/min, heart rate 150/min, systolic blood pressure 70 mm Hg, and SpO₂ 84% on supplementary oxygen. Breath sounds are absent over the right chest, and the trachea is deviated to the left. He has weak central pulses and absent distal pulses. Which of the following is the most appropriate immediate intervention for this child?
- A. Perform endotracheal intubation and call for a STAT chest x-ray
 - B. Provide bag-mask ventilation and call for a STAT chest x-ray
 - C. Establish IV access and administer a 20 mL/kg normal saline fluid bolus
 - D. Perform needle decompression of the right chest and assist ventilation with a bag and mask if necessary

For further information: see the PALS Provider Manual Chapter 4: Recognition of Shock, Chapter 5: Management of Shock, and the PALS Course Guide Part 9: Shock.

11. An 18-month-old child presents with a 1-week history of cough and runny nose. You perform a general assessment, which reveals a toddler responsive only to painful stimulation with slow respirations and diffuse cyanosis. You begin a primary assessment and find that the child's respiratory rate has fallen from 65/min to 10/min, severe inspiratory intercostal retractions are present, heart rate is 160/min, SpO₂ is 65% in room air, and capillary refill is less than 2 seconds. Which of the following is the most appropriate immediate treatment for this toddler?
- A. Establish vascular access and administer a 20 mL/kg bolus of isotonic crystalloid
 - B. Open the airway and provide positive-pressure ventilation using 100% oxygen and a bag-mask device
 - C. Administer 100% oxygen by face mask, establish vascular access, and obtain a STAT chest x-ray
 - D. Administer 100% oxygen by face mask, obtain an arterial blood gas, and establish vascular access

For further information: see the PALS Provider Manual Chapter 3: Recognition of Respiratory Distress and Failure, Chapter 4: Management of Respiratory Distress and Failure.

12. You are supervising another healthcare provider who is inserting an intraosseous (IO) needle into an infant's tibia. Which of the following signs should you tell the provider is the best indication of successful insertion of a needle into the bone marrow cavity?
- A. Pulsatile blood flow will be present in the needle hub
 - B. Fluids can be administered freely without local soft tissue swelling
 - C. You are unable to aspirate any blood through the needle
 - D. Once inserted, the needle shaft of the needle moves easily in all directions within the bone

For further information: see the PALS Provider Manual Chapter 4: Recognition of Shock, Chapter 5: Management of Shock, and the PALS Course Guide Part 9: Shock.

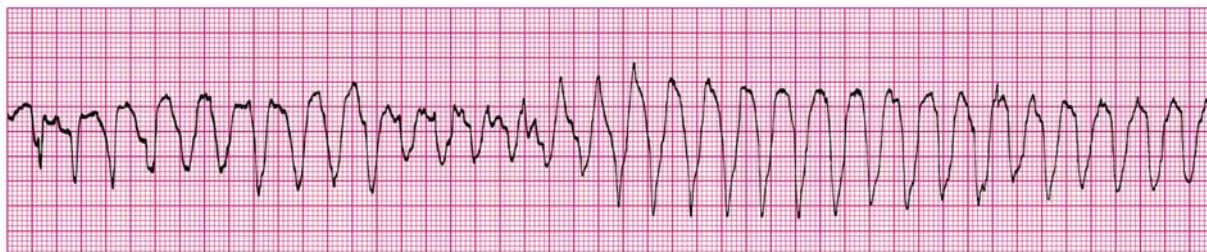
13. A pale and obtunded 3-year-old child with a history of diarrhea is brought to the hospital. Primary assessment reveals respiratory rate of 45/min with good breath sounds bilaterally. Heart rate is 150/min, blood pressure is 90/64 mm Hg, and SpO₂ is 92% in room air. Capillary refill is 5 seconds and peripheral pulses are weak. After placing the child on a nonrebreathing face mask (10 L/min flow) with 100% oxygen and obtaining vascular access, which of the following is the most appropriate immediate treatment for this child?
- A. Obtain a chest x-ray
 - B. Begin a maintenance crystalloid infusion
 - C. Administer a bolus of 20 mL/kg isotonic crystalloid
 - D. Administer a dopamine infusion at 2 to 5 ug/kg per minute

For further information: see the PALS Provider Manual Chapter 4: Recognition of Shock, Chapter 5: Management of Shock, and the PALS Course Guide Part 9: Shock.

14. You have just assisted with the elective endotracheal intubation of a child with respiratory failure and a perfusing rhythm. Which of the following provides the most reliable, prompt assessment of correct endotracheal tube placement in this child?
- A. Absence of audible breath sounds over the abdomen during positive-pressure ventilation
 - B. Auscultation of breath sounds over the lateral chest bilaterally plus presence of mist in the endotracheal tube
 - C. Confirmation of appropriate oxygen and carbon dioxide tensions on arterial blood gas analysis
 - D. Clinical assessment of adequate bilateral breath sounds and chest expansion plus presence of exhaled CO₂ in a colorimetric detection device after delivery of 6 positive-pressure ventilations

For further information: see the PALS Provider Manual Chapter 3: Recognition of Respiratory Distress and Failure, and Chapter 4: Management of Respiratory Distress and Failure.

15. A 4-year-old male is in pulseless arrest in the pediatric intensive care unit. A code is in progress. As the on-call physician you quickly review his chart and find that his baseline corrected QT interval on a 12-lead ECG is prolonged. A glance at the monitor shows recurrent episodes of the following rhythm:



The boy has received one dose of epinephrine 0.01 mg/kg (0.1 mL/kg of 1:10,000 dilution) but continues to demonstrate the rhythm illustrated above. If this rhythm persists at the next rhythm check, which medication would be *most* appropriate to administer at this time?

- A. Adenosine 0.1 mg/kg IV
- B. Epinephrine 0.1 mg/kg (0.1 mL/kg of 1:1,000 dilution) IV
- C. Lidocaine 1 mg/kg IV
- D. Magnesium sulfate 50 mg/kg IV

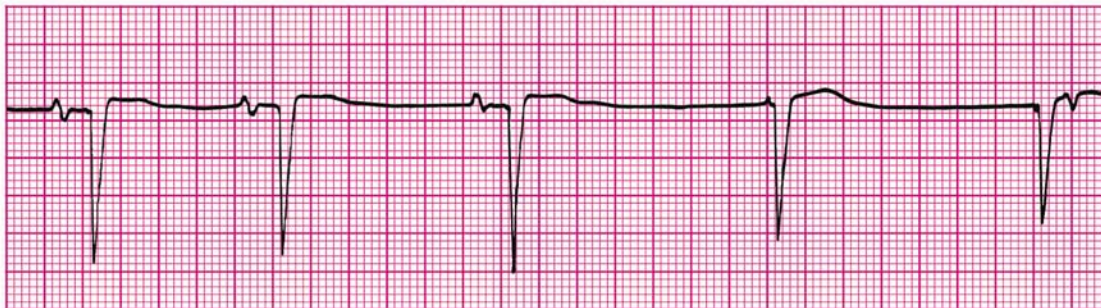
For further information: see the PALS Provider Manual Chapter 7: Recognition and Management of Cardiac Arrest, Chapter 9: Pharmacology, the PALS Course Guide Part 6: Cardiac Arrest, and Part 10: Pharmacology.

16. You are participating in the elective intubation of a 4-year-old child with respiratory failure. You must select the appropriate sized uncuffed endotracheal tube. You do not have a color-coded, length-based tape to use to estimate correct endotracheal tube size. Which of the following is the most appropriate estimated size uncuffed endotracheal tube for an average 4-year-old?
- A. 3-mm tube
 - B. 4-mm tube
 - C. 5-mm tube
 - D. 6-mm tube

For further information: see the PALS Provider Manual Chapter 3: Recognition of Respiratory Distress and Failure, and Chapter 4: Management of Respiratory Distress and Failure.

17. You are caring for a 3-year-old with vomiting and diarrhea. You have established IV access. When you place an orogastric tube, the child begins gagging and continues to gag after the tube is placed. The child's color has deteriorated; pulses are palpable but faint and the child is now lethargic. The heart rate is variable (range 44/min to 62/min). You begin bag-mask ventilation with 100% oxygen. When the heart rate does not improve, you begin chest compressions.

The cardiac monitor shows



Which of the following would be the *most* appropriate therapy to consider next?

- A. Epinephrine 0.1 mg/kg (0.1 mL/kg of 1:1,000 dilution) IV
- B. Atropine 0.02 mg/kg IV
- C. Attempt synchronized cardioversion at 0.5 J/kg
- D. Cardiology consult for transcutaneous pacing

For further information: see the PALS Provider Manual Chapter 6: Recognition and Management of Bradyarrhythmias and Tachyarrhythmias, Chapter 9: Pharmacology, the PALS Course Guide Part 7: Bradyarrhythmias and Tachyarrhythmias and Part 10: Pharmacology.

18. You are transporting a 6-year-old endotracheally intubated patient who is receiving positive-pressure mechanical ventilation. The child begins to move his head and suddenly becomes cyanotic and bradycardic. SpO₂ is 65% with good pulse signal. You remove the child from the mechanical ventilator circuit and provide manual ventilation with a bag via the endotracheal tube. During manual ventilation with 100% oxygen, the child's color and heart rate improve slightly and his blood pressure remains adequate. Breath sounds and chest expansion are present and adequate on the right side, but they are consistently diminished on the left side. The trachea is not deviated, and the neck veins are not distended. A suction catheter passes easily beyond the tip of the endotracheal tube. Which of the following is the most likely cause of this child's acute deterioration?
- A. Tracheal tube displacement into the right main bronchus
 - B. Tracheal tube obstruction
 - C. Tension pneumothorax on the right side
 - D. Equipment failure

For further information: see the PALS Provider Manual Chapter 3: Recognition of Respiratory Distress and Failure, and Chapter 4: Management of Respiratory Distress and Failure.

19. A 3-year-old boy presents with multiple system trauma. The child was an unrestrained passenger in a motor vehicle crash. On primary assessment he is unresponsive to voice or painful stimulation. His respiratory rate is <6/min, heart rate is 170/min, systolic blood pressure is 60 mm Hg, capillary refill is 5 seconds, and SpO₂ is 75% in room air. Which of the following most accurately summarizes the first actions you should take to support this child?
- A. Provide 100% oxygen by simple mask, stabilize the cervical spine, establish vascular access, and provide maintenance IV fluids
 - B. Provide 100% oxygen by simple mask and perform a head-to-toe survey to identify the extent of all injuries; begin an epinephrine infusion and titrate to maintain a systolic blood pressure of at least 76 mm Hg
 - C. Establish immediate vascular access, administer 20 mL/kg isotonic crystalloid, and reassess the patient; if the child's systemic perfusion does not improve, administer 10 to 20 mL/kg packed red blood cells
 - D. Open the airway (jaw-thrust technique) while stabilizing the cervical spine, administer positive-pressure ventilation with 100% oxygen, and establish immediate IV/IO access

For further information: see the PALS Provider Manual Chapter 3: Recognition of Respiratory Distress and Failure, and Chapter 4: Management of Respiratory Distress and Failure,

PALS Written 2006 Precourse Self-Assessment

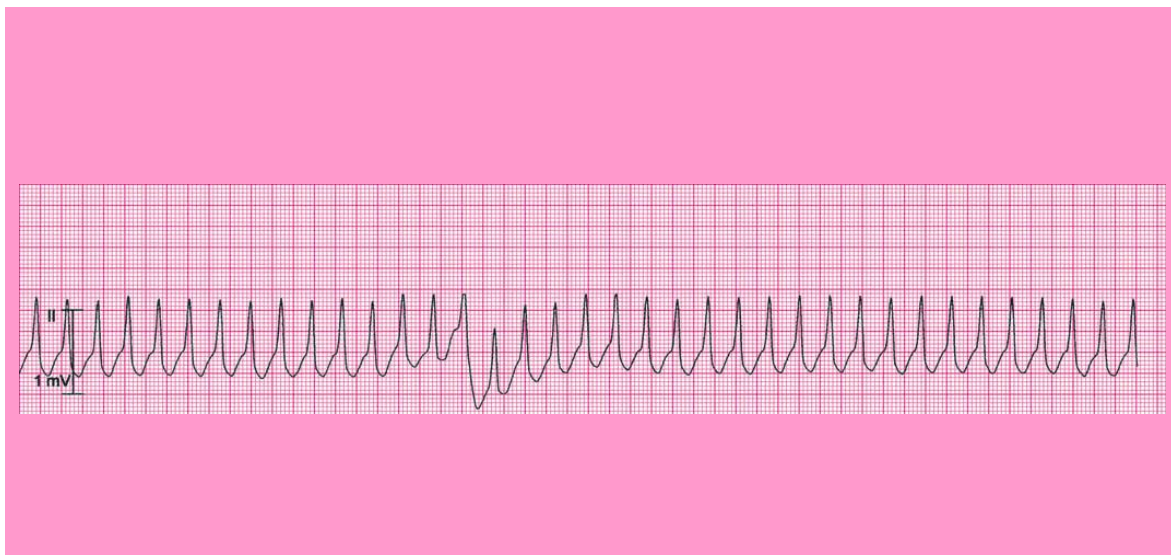
ECG Rhythm Identification Answer Sheet

Pediatric Rhythms (core PALS rhythms A to H; non-core rhythms I to M):

- A. Normal sinus rhythm
 - B. Sinus tachycardia
 - C. Sinus bradycardia
 - D. Supraventricular tachycardia (SVT)
 - E. Wide-complex tachycardia; presumed ventricular tachycardia (monomorphic)
 - F. Ventricular fibrillation (VF)
 - G. Asystole
 - H. Pulseless electrical activity (PEA)
-
- I. SVT converting to sinus rhythm with adenosine administration
 - J. Wide-complex tachycardia (in a child with known aberrant intraventricular conduction; this is SVT with aberrant conduction)
 - K. First-degree AV block
 - L. Torsades de pointes (polymorphic ventricular tachycardia)
 - M. VF converted to organized rhythm after successful shock delivery (defibrillation)

Rhythms 1 to 8: Core PALS Rhythms (select single best answer from rhythms A to H)

Rhythm 1 (clinical clue: heart rate 214/min)



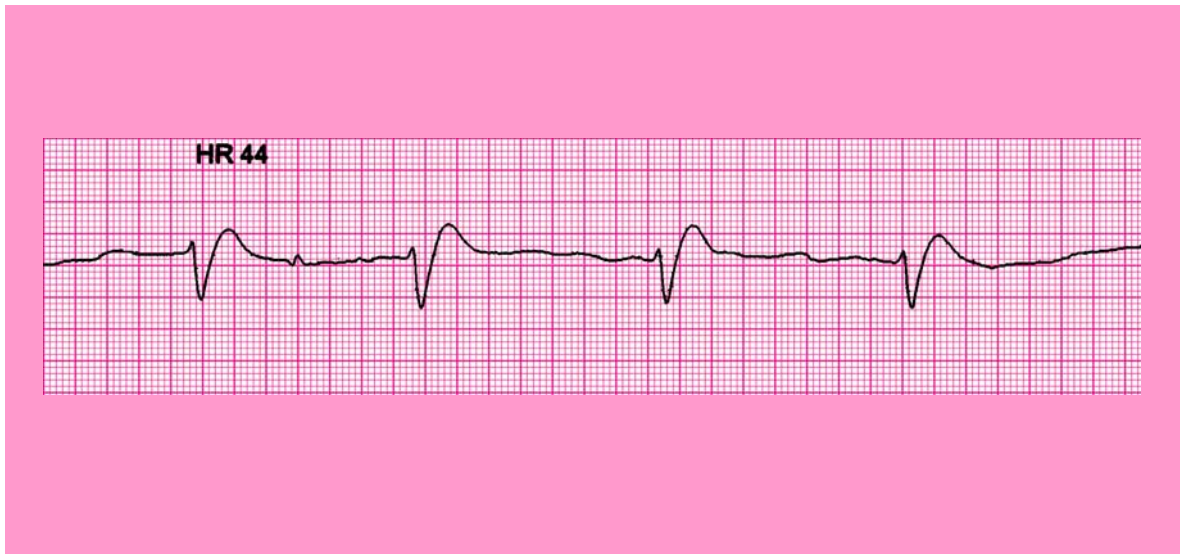
Correct answer is E: Wide-complex tachycardia; presumed ventricular tachycardia (monomorphic)

Pediatric ECG tip: Ventricular tachycardia is a sustained series of wide QRS complexes (ie, ventricular depolarizations) typically at a rate of at least 120/min. This VT can be further classified as monomorphic because all complexes have the same appearance. If

this rhythm is observed in a child with no history of aberrant intraventricular conduction and no aberrant conduction apparent on 12-lead ECG, the rhythm should be presumed to be ventricular tachycardia.

For further information: see the PALS Provider Manual Chapter 6: Recognition and Management of Bradyarrhythmias and Tachyarrhythmias and Chapter 7: Recognition and Management of Cardiac Arrest.

Rhythm 2 (clinical clues: heart rate 44/min; no detectable pulses)

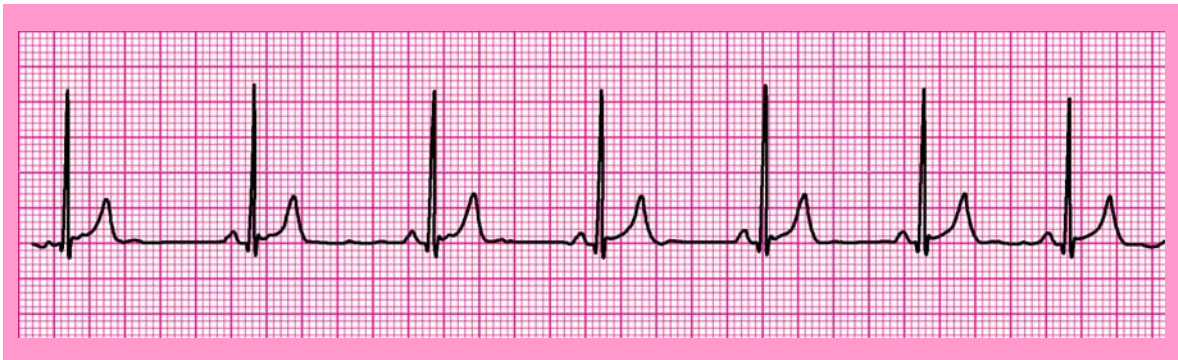

Correct answer is H: Pulseless electrical activity (PEA)

Pediatric ECG tip: In the absence of detectable pulses, this organized rhythm is one of the cardiac arrest rhythms—Pulseless electrical activity (PEA) (PEA). It is treated using the asystole/PEA portion of the PALS Pulseless Arrest algorithm. This particular rhythm may be described as an *idioventricular escape rhythm* (an escape rhythm originating from a slow ventricular pacemaker during periods of significant sinus bradycardia or high-grade AV block). It is characterized by wide QRS complexes, and it is often seen in the setting of a severely hypoxic-ischemic myocardium.

For further information: see the PALS Provider Manual Chapter 6: Recognition and Management of Bradyarrhythmias and Tachyarrhythmias.

Rhythm 3 (clinical clues: age 8 years; heart rate 50/min)

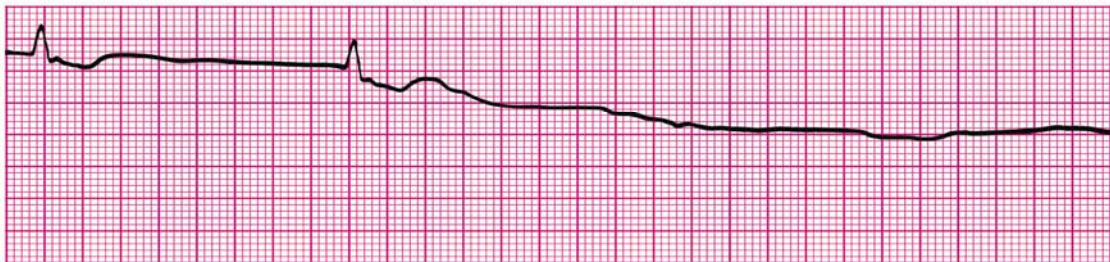


Correct answer is C: Sinus bradycardia.

Pediatric ECG tip: Sinus bradycardia is characterized by a sinus rhythm with a rate that is slower than normal for the patient's age. P waves and QRS complexes are usually normal in appearance; the QRS is narrow.

For further information: see the PALS Provider Manual Chapter 6: Recognition and Management of Bradyarrhythmias and Tachyarrhythmias.

Rhythm 4 (clinical clue: no detectable pulses)

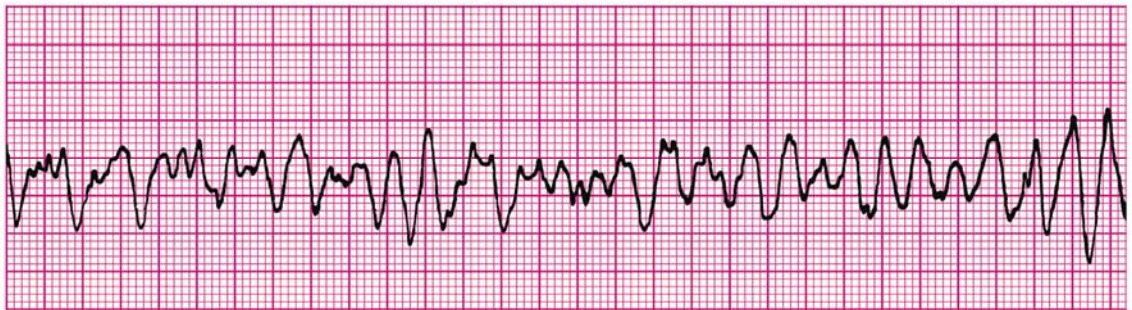


Correct answer is G: Asystole

Pediatric ECG tip: Asystole is the absence of ventricular depolarization (ie, cardiac standstill). It may be preceded by an agonal (usually wide-complex) bradyarrhythmia (see an example of this in Rhythm 2). When you observe this rhythm in a child who is unresponsive, apneic, and pulseless, you should begin compressions and ventilations (CPR) immediately. Of course, if you are uncertain whether the rhythm is asystole, confirm the flat-line rhythm in 2 perpendicular leads but do not delay CPR for an unresponsive, apneic child.

For further information: see the PALS Provider Manual Chapter 7: Recognition and Management of Cardiac Arrest.

Rhythm 5 (clinical clue: no consistent heart rate detected; no detectable pulses)

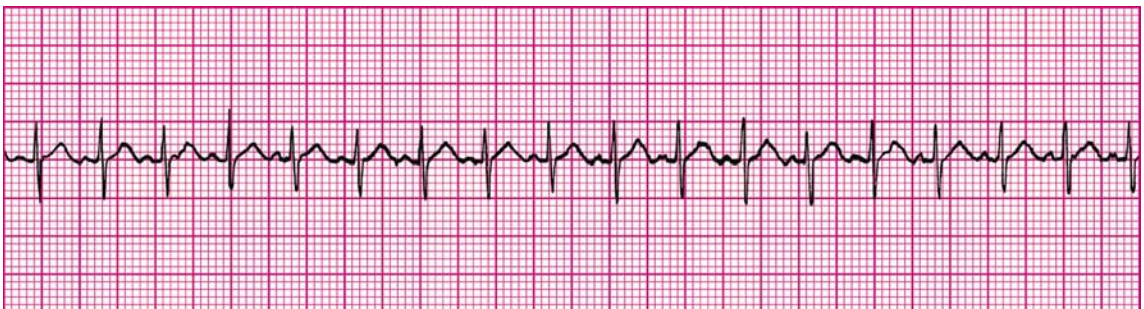


Correct answer is F: Ventricular fibrillation

Pediatric ECG tip: Ventricular fibrillation (VF) is characterized by a rapid, irregular waveform of varying size and configuration. VF begins as a coarse, irregular deflection and then deteriorates to a fine, irregular pattern. If no CPR and no shocks are provided, this rhythm will eventually progress to asystole.

For further information: see the PALS Provider Manual Chapter 7: Recognition and Management of Cardiac Arrest.

Rhythm 6 (clinical clues: age 3 years; heart rate 188/min)



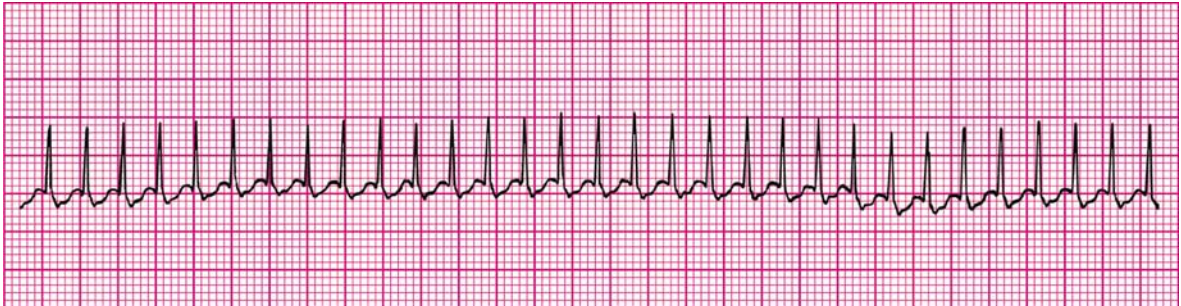
Correct answer is B: Sinus tachycardia

Pediatric ECG tip: Sinus tachycardia is characterized by a normal sequence of impulse

formation and conduction with a rate faster than normal for the patient's age. P waves precede each QRS complex; the QRS is typically narrow.

For further information: see the PALS Provider Manual Chapter 6: Recognition and Management of Bradyarrhythmias and Tachyarrhythmias.

Rhythm 7 (clinical clue: heart rate 300/min)

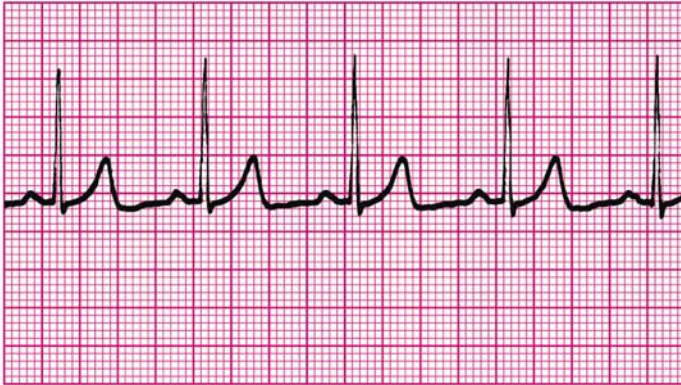


Correct answer is D: Supraventricular tachycardia

Pediatric ECG tip: Supraventricular tachycardia is characterized by the following: no beat-to-beat variability with activity or stimulation; heart rate typically >220/min in infants and >180/min in children; absent or abnormal P waves; and usually narrow QRS complexes. Wide-complex tachycardia with poor perfusion is probably ventricular in origin, but one pediatric case series and clinical experience note that it may be supraventricular with aberrant intraventricular conduction.

For further information: see the PALS Provider Manual Chapter 6: Recognition and Management of Bradyarrhythmias and Tachyarrhythmias.

Rhythm 8 (clinical clues: age 8 years; heart rate 75/min)

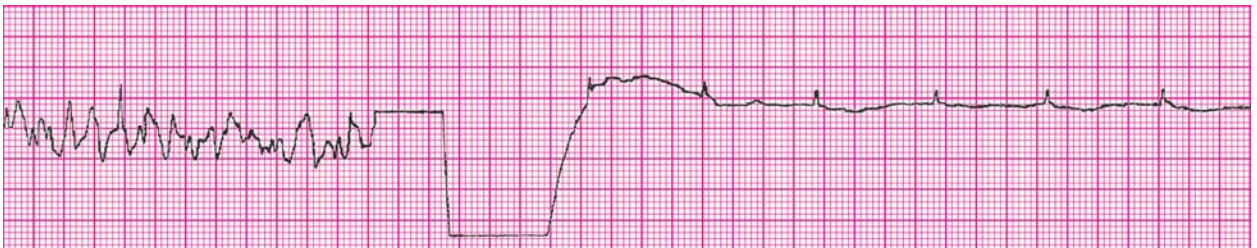

Correct answer is A: Normal sinus rhythm

Pediatric ECG tip: All rhythms originating in the sinoatrial (sinus) node are characterized by the following: P waves preceding each QRS complex; regular PR interval; all of the P waves are upright and have the same appearance. The QRS complexes are narrow in this strip. In normal sinus rhythm, the heart rhythm is regular, heart rate is normal for the patient's age, and the rate changes with activity.

Rhythms 9 to 13: Non-core Rhythms

Rhythm 9 (clinical clue: initial rhythm associated with no detectable pulses)

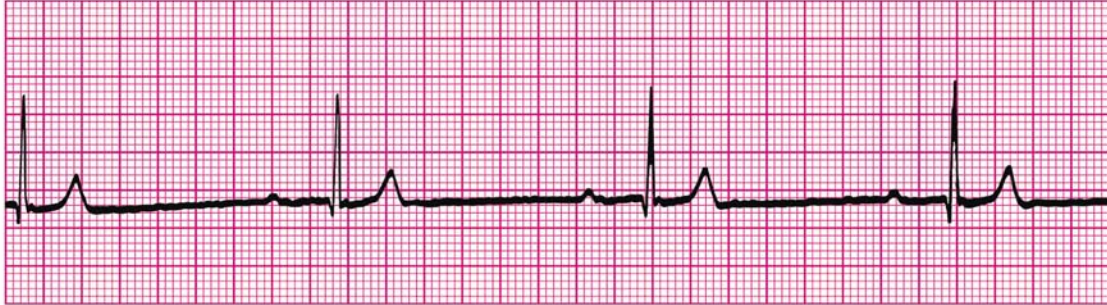


Correct answer is M: Ventricular fibrillation converted to organized rhythm after successful shock delivery (defibrillation)

Pediatric ECG tip: The probability of successful defibrillation is greater the higher the amplitude of the VF waveform (ie, when the VF waveform is "coarse"). The probability of successful defibrillation decreases as the amplitude of the VF waveform decreases (ie, the VF waveform becomes more "fine"). Fine VF is consistent with an ischemic myocardium that has exhausted its oxygen supply and energy substrates.

For further information: see PALS Provider Manual Chapter 7: Recognition and Management of Cardiac Arrest

Rhythm 10 (clinical clues: age 9 months; heart rate 38/min)

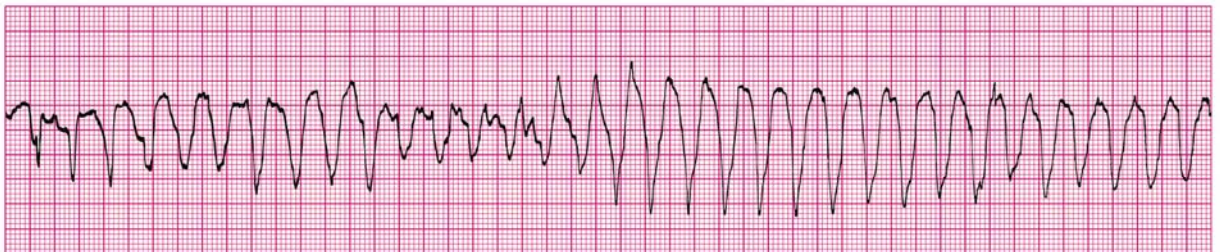


Correct answer is C and K: Sinus bradycardia with first-degree AV block

Pediatric ECG tip: There is an atrial depolarization (P wave) before each QRS complex, but the rate is less than 60/min, so this defines sinus bradycardia in an infant or child. First-degree AV block represents a delay in conduction through the AV node. The PR interval is prolonged beyond the upper limit of normal for the patient's age and heart rate. In this strip the QRS complexes are narrow. Every P wave is followed by a QRS complex, so the heart block is first degree. (Note that this example of first-degree AV block is associated with sinus bradycardia. In the clinical setting children may have one or more rhythm disturbances at the same time.)

For further information: see the PALS Provider Manual Chapter 6: Recognition and Management of Bradyarrhythmias and Tachyarrhythmias.

Rhythm 11 (clinical clues: heart rate 200/min; no detectable pulses)



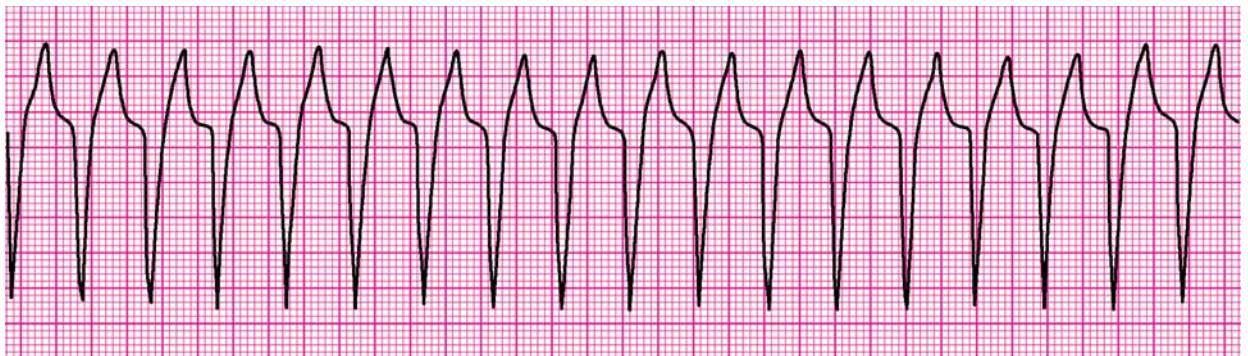
Correct answer is L: Torsades de pointes (polymorphic ventricular tachycardia)

Pediatric ECG tip: Torsades de pointes (“twisting of the points”) is a distinctive form of polymorphic VT. It is characterized by QRS complexes that change in amplitude and polarity in a cyclic pattern so that they appear to rotate around an isoelectric line. The ventricular rate can range from 150 to 250/min. Characteristically when the patient was in sinus rhythm, torsades de pointes is associated with a markedly prolonged QT interval. (This QT interval cannot be measured during the tachycardia.) Even if the patient with torsades has pulses

initially, the patient will quickly become pulseless. Any pulseless VT is a cardiac arrest rhythm, and it is treated with CPR and attempted defibrillation. Torsades is also treated with IV magnesium according to the VF/pulseless VT portion of the PALS Pulseless Arrest Algorithm.

For further information: see the PALS Provider Manual Chapter 6: Recognition and Management of Bradyarrhythmias and Tachyarrhythmias and Chapter 7: Recognition and Management of Cardiac Arrest.

Rhythm 12 (clinical clue: heart rate 150/min)

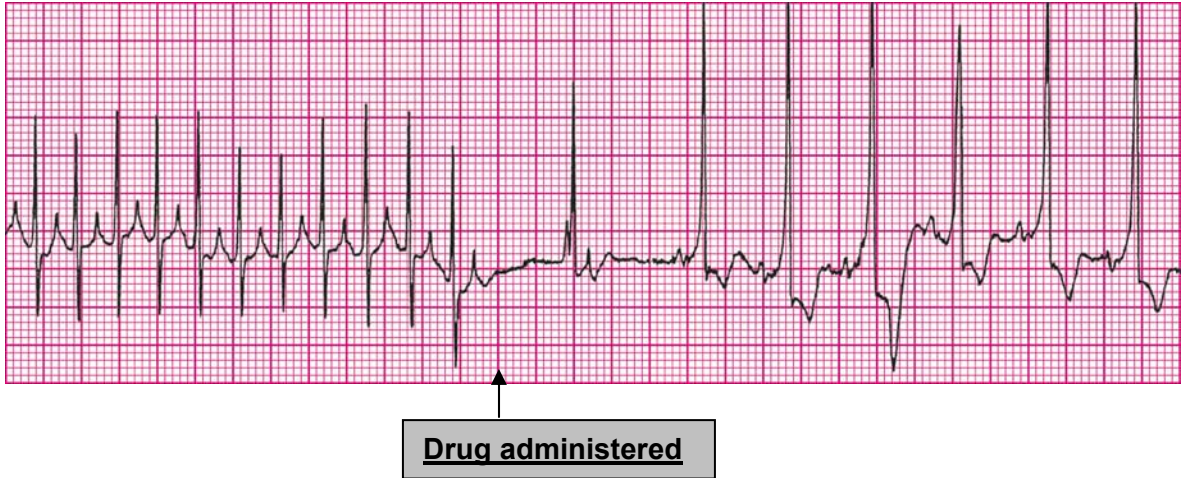


Correct answer is J: Wide-complex tachycardia (in child with known aberrant intraventricular conduction, this is SVT with aberrant conduction)

Pediatric ECG tip: The wide QRS complex seen in this strip is supraventricular tachycardia with aberrant intraventricular conduction, which may be due to abnormal bundle branch conduction (eg, preexisting bundle branch block or rate-related malfunction) or abnormal accessory pathway AV conduction (eg, as encountered in preexcitation syndromes such as that described by Wolff, Parkinson, and White). Without a 12-lead ECG or a history of known aberrant conduction, it is impossible to distinguish this rhythm from ventricular tachycardia. For this reason the provider should assume that a wide-complex tachycardia is VT unless the child is known to have aberrant conduction. Treatment is dictated by the child's clinical condition (poor perfusion versus adequate perfusion).

For further information: see the PALS Provider Manual Chapter 6: Recognition and Management of Bradyarrhythmias and Tachyarrhythmias.

Rhythm 13 (clinical clue: initial rhythm associated with heart rate 300/min)



Correct answer is I: Supraventricular tachycardia converting to sinus rhythm with adenosine administration

Pediatric ECG tip: Supraventricular tachycardia is present at the beginning of this strip. SVT that involves the AV node is terminated when transient AV block is produced by adenosine. Adenosine causes transient sinus arrest or bradycardia following bolus administration, resulting in a sinus pause lasting several seconds. The subsequent rhythm has a sinus origin, but the QRS is prolonged with ST-segment depression and T-wave inversion. This rhythm disturbance may be seen with ischemic myocardium or in the setting of myocarditis or myocardial injury following heart surgery.

For further information: see the PALS Provider Manual Chapter 6: Recognition and Management of Bradyarrhythmias and Tachyarrhythmias.

Pharmacology Answer Sheet

1. You are called to help resuscitate an infant with severe symptomatic bradycardia associated with respiratory distress. The bradycardia persists despite establishment of an effective airway, oxygenation, and ventilation. There is no heart block present. Which of the following is the *first drug* you should administer?
- A. Atropine
 - B. Dopamine
 - C. Adenosine
 - D. Epinephrine**

Correct answer is D. Epinephrine, a catecholamine with direct effects at the β -adrenergic receptor, is the first drug recommended for severe symptomatic bradycardia unresponsive to establishment and support of the airway, oxygenation, and ventilation. Epinephrine is preferred in this setting because it more effectively improves the heart rate in a hypoxic-ischemic myocardium, which is the most common cause of severe symptomatic bradycardia in children.

Answer A is incorrect. Atropine is indicated only if you suspect that the bradycardia is vagally induced or associated with heart block. Note that some drug toxicities produce increased vagal tone (eg, digoxin overdose). Primary atrioventricular (AV) block is another indication for using atropine preferentially over epinephrine in the treatment of symptomatic bradycardia.

Answer B is incorrect. Dopamine is not included in the PALS treatment algorithm for severe symptomatic bradycardia. It takes time to prepare a dopamine infusion.

Answer C is incorrect. Adenosine blocks AV conduction and is used to treat supraventricular tachycardia. It is not recommended for the treatment of severe symptomatic bradycardia.

For further information: see the PALS Provider Manual Chapter 6: Recognition and Management of Bradyarrhythmias and Tachyarrhythmias, Chapter 9: Pharmacology, and the PALS Course Guide Part 10: Pharmacology.

2. Which of the following statements about the effects of epinephrine during attempted resuscitation is true?
- A. Epinephrine decreases peripheral vascular resistance and reduces myocardial afterload so that ventricular contractions are more effective
 - B. Epinephrine improves coronary artery perfusion pressure and stimulates spontaneous contractions when asystole is present**
 - C. Epinephrine is contraindicated in ventricular fibrillation because it increases myocardial irritability
 - D. Epinephrine decreases myocardial oxygen consumption

Correct answer is B. Epinephrine improves coronary artery perfusion pressure and myocardial oxygen delivery during CPR by increasing peripheral vascular resistance and thus aortic diastolic pressure. Recall that coronary perfusion pressure is determined by the difference between aortic end-diastolic pressure and right atrial end-diastolic pressure. Epinephrine also stimulates spontaneous cardiac contractions through its β -adrenergic agonist effects, so it may restore cardiac activity when asystole is present. Increases in heart rate, cardiac contractility, and systemic vascular resistance increase myocardial oxygen demand.

Answer A is incorrect. Epinephrine *increases* peripheral vascular resistance, ventricular afterload, and oxygen demand.

Answer C is incorrect. Epinephrine is useful in the treatment of ventricular fibrillation. It increases the coarseness of ventricular fibrillation, which likely reflects improved coronary artery perfusion, thereby enhancing the potential for termination of ventricular fibrillation by attempted defibrillation.

Answer D is incorrect. Epinephrine *increases* myocardial oxygen consumption. Although epinephrine-induced elevation of coronary artery perfusion pressure during chest compressions enhances delivery of oxygen to the heart, oxygen consumption is increased, not decreased.

For further information: see the PALS Provider Manual Chapter 9: Pharmacology, and the PALS Course Guide Part 10: Pharmacology.

3. **General assessment of a 2-year-old female reveals her to be alert with mild breathing difficulty during inspiration and pale skin color. On primary assessment, she makes high-pitched inspiratory sounds (mild stridor) when agitated; otherwise her breathing is quiet. Her SpO₂ is 92% in room air, and she has mild inspiratory intercostal retractions. Lung auscultation reveals transmitted upper airway sounds with adequate distal breath sounds bilaterally. Which of the following is the most appropriate initial therapy intervention for this child?**
- A. Perform immediate endotracheal intubation
 - B. Administer an IV dose of dexamethasone
 - C. Nebulize 2.5 mg of albuterol
 - D. **Administer humidified supplementary oxygen as tolerated and continue evaluation**

Correct answer is D. This child is not in acute distress and has no clinical evidence of respiratory failure. Therefore, the most appropriate intervention is to provide humidified oxygen as tolerated and observe the child to determine if she improves, deteriorates, or stays the same.

Answer A is incorrect. This child does not meet the criteria for intubation. If you determine that the child has upper airway obstruction and cannot maintain an airway or if the child demonstrates signs of fatigue or respiratory failure, then endotracheal intubation is

indicated. Intubation of the child with upper airway obstruction can be very difficult, and it should be performed by a provider experienced in airway management.

Answer B is incorrect. Dexamethasone may be an appropriate therapeutic intervention for this child, it but would be given orally if indicated rather than IV.

Answer C is incorrect. Although this child has noisy breathing, the breathing abnormality occurs during inspiration, indicating that this is upper airway obstruction. Albuterol is not helpful for upper airway obstruction. Either nebulized racemic epinephrine or L-epinephrine (ie, IV form of epinephrine) would be appropriate if the child were more symptomatic.

For further information: see the PALS Provider Manual Chapter 2: Recognition of Respiratory Distress and Failure, Chapter 3: Management of Respiratory Distress and Failure, Chapter 9: Pharmacology, and the PALS Course Guide Part 10: Pharmacology.

4. Which of the following most reliably delivers a high (90% or greater) concentration of inspired oxygen in a toddler or older child?
- A. Nasal cannula with 4 L/min oxygen flow
 - B. Simple oxygen mask with 15 L/min oxygen flow
 - C. Nonbreathing face mask with 12 L/min oxygen flow**
 - D. Face tent with 15 L/min oxygen flow

Correct answer is C. With an oxygen flow of 10 to 12 L/min and a good seal between the patient's face and mask, a nonbreathing face mask with an oxygen reservoir can provide an inspired oxygen concentration of approximately 95%.

Answer A is incorrect. A nasal cannula cannot reliably provide a high concentration of inspired oxygen to a toddler or older child. The inspired oxygen concentration provided by a nasal cannula varies based on the patient's respiratory rate, size (ie, tidal volume), and oxygen flow rate. Although a nasal cannula delivers higher inspired oxygen concentrations to infants than to older children, an oxygen concentration greater than 90% is difficult to achieve, particularly if the infant breathes through the mouth.

Answer B is incorrect. A simple oxygen mask permits entrainment of room air even when a high flow of oxygen is attached to the mask. A simple oxygen mask delivers only about 35% to 60% oxygen with a flow rate of 6 to 10 L/min.

Answer D is incorrect. A face tent still permits entrainment of room air at a rate that varies with the child's respiratory rate, respiratory effort, and size (ie, tidal volume). It can be difficult to keep the face tent in place. Even with a high oxygen flow rate of 10 to 15 L/min, stable inspired oxygen concentrations >40% cannot be reliably provided with a face tent.

5. Which of the following statements about endotracheal drug administration is true?
- A. Endotracheal drug administration is the preferred route of drug administration during resuscitation because it results in predictable drug levels and drug effects
 - B. Endotracheal doses of resuscitation drugs in children have been well established and are supported by evidence from clinical trials
 - C. Intravenous drug doses for resuscitation drugs should be used whether you give the drugs by the IV, intraosseous (IO), or the endotracheal route
 - D. Endotracheal drug administration is the least desirable route of administration because this route results in unpredictable drug levels and effects**

Correct answer is D. Endotracheal (ET) drug administration is the least desirable route of resuscitation drug administration because optimal doses are unknown and this route results in unpredictable drug levels and effects. In fact, poor absorption of epinephrine by ET route may result in relatively low plasma concentration of epinephrine during resuscitation. Evidence from animal models suggests that the low epinephrine plasma concentrations following ET administration may result in preferential stimulation of β_2 -adrenergic receptors (producing vasodilation) rather than the α -adrenergic receptors that would produce the vasoconstriction needed during resuscitation.

Answers A and B are incorrect. There is limited clinical evidence about optimal drug doses to be administered by the ET route to produce specific drug concentrations and effects.

Answer C is incorrect. Although evidence is limited, it is clear that higher doses than those used for IV/IO route of administration should be used when drugs are administered by ET route.

For further information: see the PALS Provider Manual Chapter 7: Recognition and Management of Cardiac Arrest, Chapter 9: Pharmacology, and the PALS Course Guide Part 10: Pharmacology.

6. Which of the following statements most accurately reflects the PALS recommendations for the use of magnesium sulfate in the treatment of cardiac arrest?
- A. Magnesium sulfate is indicated for VF refractory to repeated shocks and amiodarone or lidocaine
 - B. Routine use of magnesium sulfate is indicated for shock-refractory monomorphic VT
 - C. Magnesium sulfate is indicated for torsades de pointes or suspected hypomagnesemia**
 - D. Magnesium sulfate is contraindicated in VT associated with an abnormal QT interval during the preceding sinus rhythm

Correct answer is C. Acting as an antiarrhythmic agent, magnesium sulfate is the *drug of choice* for treatment of torsades de pointes (“twisting of the point”), a distinctive form of polymorphic VT. Torsades is characterized by QRS complexes that change in amplitude and polarity with each beat so that they appear to rotate around an isoelectric line. Magnesium sulfate is also recommended for pulseless VT/VF associated with suspected hypomagnesemia.

Answer A is incorrect. Magnesium sulfate is not recommended for VF refractory to repeated shocks, amiodarone, or lidocaine. There is insufficient evidence to recommend the routine use of magnesium sulfate in the treatment of pediatric cardiac arrest.

Answer B is incorrect. Routine use of magnesium sulfate is not recommended for shock-refractory monomorphic VT. Two observational studies in adults, however, showed that magnesium alone is effective in the treatment of polymorphic VT (eg, torsades de pointes) in patients with prolonged QT interval.

Answer D is incorrect. Magnesium sulfate is indicated in VT associated with a prolonged QT interval during the sinus rhythm that preceded the development of torsades de pointes. Characteristically torsades de pointes is associated with a markedly prolonged baseline QT interval before the onset of the arrhythmia. Note that the QT interval must be evaluated during sinus rhythm and cannot be measured during an episode of ventricular tachycardia.

For further information: see the PALS Provider Manual Chapter 6: Recognition and Management of Bradyarrhythmias and Tachyarrhythmias, Chapter 7: Recognition and Management of Cardiac Arrest, Chapter 9: Pharmacology, and the PALS Course Guide Part 10: Pharmacology.

7. You enter a room to perform a general assessment of a previously stable 10-year-old male and find him unresponsive and apneic. A code is called and bag-mask ventilation is performed with 100% oxygen. The cardiac monitor shows a wide-complex tachycardia. The boy has no detectable pulses. You deliver an unsynchronized shock with 2 J/kg. The rhythm check after 2 minutes of CPR reveals VF. You then deliver a shock of 4 J/kg and resume immediate CPR beginning with compressions. A team member had established IO access, so you give a dose of epinephrine, 0.01 mg/kg (0.1 mL/kg of 1:10,000 dilution) IO when CPR is restarted after the second shock. At the next rhythm check, persistent VF is present. You administer a 4 J/kg shock and resume CPR. Based on the PALS Pulseless Arrest Algorithm, what are the next drug and dose to administer when CPR is restarted?
- A. Epinephrine 0.1 mg/kg (0.1 mL/kg of 1:1,000 dilution) IO
 - B. Atropine 0.02 mg/kg IO
 - C. Amiodarone 5 mg/kg IO**
 - D. Magnesium sulfate 25 to 50 mg/kg IO

Correct answer is C. The data supporting the use of amiodarone in the treatment of life-threatening ventricular arrhythmias in children is extrapolated from adult studies showing short-term beneficial effects for treatment of shock-refractory VF or VT. In addition, amiodarone has been reported to be effective in the treatment of atrial and ventricular arrhythmias in children. Amiodarone is recommended as part of the treatment of shock-refractory or recurrent VT. Amiodarone inhibits α -adrenergic and β -adrenergic receptors, producing vasodilation and AV nodal suppression (ie, impaired conduction through the AV node). Amiodarone also inhibits the outward potassium current, thereby

prolonging the QT interval. Amiodarone slows AV conduction, prolongs the AV refractory period and QT interval, and slows ventricular conduction (widens the QRS).

Answer A is incorrect. There is no survival benefit from routine use of *high-dose* epinephrine, and it may be harmful, particularly in asphyxial arrest. High-dose epinephrine may be considered for special resuscitation circumstances, eg. calcium channel blocker overdose or β -adrenergic blocker overdose.

Answer B is incorrect. There is no evidence that atropine improves outcome from pediatric cardiac arrest. The only evidence supporting the use of atropine in cardiac arrest is from adult patients with a slow PEA. Thus, atropine is not indicated for refractory VF cardiac arrest in children.

Answer D is incorrect. Magnesium sulfate is the drug of choice for treatment of torsades de pointes and can be given for pulseless VT or VF with suspected hypomagnesemia. There is insufficient data to recommend the routine use of magnesium sulfate for pediatric cardiac arrest.

For further information: see the PALS Provider Manual Chapter 7: Recognition and Management of Cardiac Arrest, Chapter 9: Pharmacology, and the PALS Course Guide Part 10: Pharmacology.

8. **Parents of a 1-year-old female phoned the Emergency Response System when they picked up their daughter from the baby-sitter. Paramedics perform a general assessment revealing an obtunded infant with irregular breathing, bruises over the abdomen, abdominal distention, and cyanosis. Assisted bag-mask ventilation with 100% oxygen is initiated. On primary assessment heart rate is 36/min, peripheral pulses cannot be palpated, and central pulses are barely palpable. Cardiac monitor shows sinus bradycardia. Chest compressions are started with a 15:2 compression-to-ventilation ratio. In the emergency department the infant is intubated and ventilated with 100% oxygen, and IV access is established. The heart rate is now up to 150/min but there are weak central pulses and no distal pulses. Systolic blood pressure is 74 mm Hg. Of the following, which would be most useful in management of this infant?**
- A. Epinephrine 0.01 mg/kg (0.1 mL/kg of 1:10,000 dilution) IV
 - B. Rapid bolus of 20 mL/kg of isotonic fluid**
 - C. Atropine 0.02 mg/kg IV
 - D. Synchronized cardioversion

Correct answer is B. This infant is in shock with poor perfusion, most likely secondary to inflicted trauma. The most important initial therapy is to give isotonic fluid rapidly and anticipate the need to give blood. In addition, you should consult a trauma surgeon.

Answer A is incorrect. Epinephrine is not indicated in the treatment of this patient with hypovolemic shock. The child's blood pressure is borderline acceptable but the exam confirms poor perfusion, and rather than using a vasoconstrictor, this infant needs rapid fluid resuscitation.

Answer C is incorrect. Atropine is indicated in the treatment of symptomatic bradycardia unresponsive to oxygenation and ventilation if increased vagal tone or primary AV block is suspected. This child's heart rate increased when oxygenation and ventilation were provided.

Answer D is incorrect. This child's tachycardia is a sinus tachycardia. The poor perfusion is likely the result of trauma and hypovolemia. The tachycardia should not be treated with synchronized cardioversion.

For further information: see the PALS Provider Manual Chapter 6: Recognition and Management of Bradyarrhythmias and Tachyarrhythmias, Chapter 9: Pharmacology, and the PALS Course Guide Part 10: Pharmacology.

9. Which of the following statements about calcium is true?

- A. Routine administration of calcium is not indicated during cardiac arrest.**
- B. The recommended dose is 1 to 2 mg/kg of calcium chloride
- C. Calcium chloride 10% has the same bioavailability of elemental calcium as calcium gluconate in critically ill children
- D. Indications for administration of calcium include hypercalcemia, hypokalemia, and hypomagnesemia

Correct answer is A. Routine administration of calcium is not recommended for the treatment of cardiac arrest because there is insufficient evidence that it improves outcome. In addition, several studies have implicated cytoplasmic calcium accumulation in the final common pathway of cell death. Calcium accumulation in cells occurs after ischemia and during reperfusion of ischemic organs. Therefore, routine administration of calcium during resuscitation of children in pulseless arrest cannot be recommended.

Answer B is incorrect. There is little high-quality data about the optimal emergency dose of calcium, but clinical experience shows that the recommended dose is approximately 20 mg/kg of calcium chloride or 5 to 7 mg/kg of elemental calcium.

Answer C is incorrect. Calcium chloride 10% (100 mg/mL) is the calcium preparation of choice in critically ill children because it provides greater bioavailability of calcium than calcium gluconate. Free calcium is released by calcium gluconate after hepatic metabolism, so it does not appear to be as rapidly effective. A dose of 0.2 mL/kg of 10% calcium chloride will provide 20 mg/kg of the salt and 5.4 mg/kg of elemental calcium. Further doses should be based on measured deficits of ionized calcium.

Answer D is incorrect. Indications for administration of calcium include hypocalcemia and hyperkalemia, and it may be considered for the treatment of hypermagnesemia and calcium channel blocker overdose. Hypokalemia and hypomagnesemia will not be aided by calcium administration. Ionized hypocalcemia is relatively common in critically ill children, particularly those with sepsis.

For further information: see the PALS Provider Manual Chapter 9: Pharmacology, and the PALS Course Guide Part 10: Pharmacology.

-
10. An infant with a history of vomiting and diarrhea arrives by ambulance. During your primary assessment the infant responds only to painful stimulation. The upper airway is patent, the respiratory rate is 40/min with good bilateral breath sounds, and 100% oxygen is being administered. The infant has cool extremities, weak pulses, and a capillary refill time of more than 5 seconds. The infant's blood pressure is 85/65 mm Hg, and glucose concentration (measured by bedside test) is 30 mg/dL. Which of the following is the most appropriate treatment to provide for this infant?
- A. Establish IV or IO access and administer 20 mL/kg D50.45% sodium chloride bolus over 15 minutes
 - B. Establish IV or IO access and administer 20 mL/kg Lactated Ringer's solution over 60 minutes
 - C. Perform endotracheal intubation and administer epinephrine 0.1 mg/kg 1:1,000 via the endotracheal tube
 - D. Establish IV or IO access, administer 20 mL/kg isotonic crystalloid over 10 to 20 minutes, and simultaneously administer D25W 2 to 4 mL/kg in a separate infusion**

Correct answer is D. This infant is in shock with signs of poor perfusion (cool extremities, weak pulses, and prolonged capillary refill). The history of vomiting and diarrhea suggests that hypovolemic shock is present, so immediate volume resuscitation is needed. The infant is also hypoglycemic (lowest acceptable glucose concentration for an infant is 60 mg/dL) and requires an intravenous infusion of dextrose (glucose). IV dextrose is commonly administered as D₂₅W 2 to 4 mL/kg or D₁₀W 5 to 10 mL/kg, both equal to 0.5 to 1 g/kg. Reassess the infant's perfusion after the bolus and reassess the serum glucose concentration after administration of dextrose.

Answer A is incorrect. You should not routinely use glucose solutions for volume resuscitation. In addition, you should use an isotonic rather than hypotonic (ie, 0.45% NaCl) fluid for volume resuscitation. Administer glucose separately if the patient has documented hypoglycemia.

Answer B is incorrect. Fluid resuscitation in an infant with signs of shock should be accomplished rapidly by administration of 20 mL/kg boluses over 20 minutes or less. Administration of fluids over 60 minutes is too slow to restore intravascular volume and improve systemic perfusion.

Answer C is incorrect. This infant's airway and breathing appear to be adequate at this time. Therefore, the first priority for resuscitation in this infant with signs of hypovolemic shock is support of circulation with volume administration. Volume administration should not be delayed to perform endotracheal intubation. Furthermore, there is no indication for epinephrine administration. This infant requires volume administration and dextrose, which should be provided without delay.

For further information: see the PALS Provider Manual Chapter 4: Recognition of Shock, Chapter 5: Management of Shock, Chapter 9: Pharmacology, and the PALS Course Guide Part 10: Pharmacology.

11. General assessment of a 9-year-old male with increased work of breathing. reveals the boy to be agitated and leaning forward on the bed with obvious respiratory distress. You administer 100% oxygen by nonrebreathing mask. The patient is speaking in short phrases and tells you that he has asthma but does not carry an inhaler. He has nasal flaring, severe suprasternal and intercostal retractions, and decreased air movement with prolonged expiratory time and wheezing. His SpO₂ is 92% (on nonrebreathing mask). What is the next medical therapy to provide to this patient?
- A. Adenosine 0.1 mg/kg
 - B. Amiodarone 5 mg/kg IV/IO
 - C. Albuterol by nebulization**
 - D. Procainamide 15 mg/kg IV/IO

Correct answer is C. Albuterol (salbutamol outside of the United States) is a β_2 -adrenergic agonist bronchodilator and an essential element of first-line therapy in status asthmaticus. Albuterol mediates bronchodilation via stimulation of β_2 -adrenergic receptors in airway smooth muscle, which in turn produces smooth-muscle relaxation. Albuterol is preferred over epinephrine for its relative β_2 -adrenergic selectivity, with decreased likelihood of β_1 -adrenergic cardiovascular effects. Albuterol can be administered by inhaled (via nebulization or MDI) and oral routes; orally administered albuterol is ineffective in severe asthma. It is also important to recall that combined nebulized treatments with albuterol and ipratropium bromide are recommended in children with severe asthma as illustrated in this case.

Answer A is incorrect. Adenosine is not indicated in the treatment of asthma.

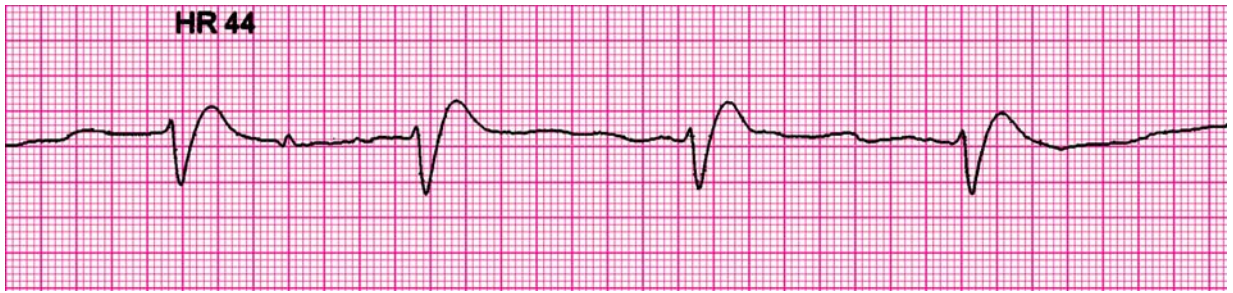
Answer B is incorrect. Amiodarone is not indicated in the treatment of asthma.

Answer D is incorrect. Procainamide is not indicated in the treatment of asthma.

For further information: see the PALS Provider Manual Chapter 3: Recognition of Respiratory Distress and Failure, Chapter 4: Management of Respiratory Distress and Failure, Chapter 9: Pharmacology, and the PALS Course Guide Part 10: Pharmacology.

Practical Application Answer Sheet

1. An 8-month-old male is brought to the emergency department (ED) for evaluation of severe diarrhea and dehydration. In the ED the child becomes unresponsive and pulseless. You shout for help and start CPR at a compression rate of 100/min and a compression-to-ventilation ratio of 30:2. Another provider arrives, at which point you switch to 2-rescuer CPR with a compression-to-ventilation ratio of 15:2. The cardiac monitor shows the following rhythm:



The infant is intubated and ventilated with 100% oxygen. An IO line is rapidly established and a dose of epinephrine is given. Of the following choices for management, which would be most appropriate to give next?

- A. Defibrillation 2 J/kg
- B. Normal saline 20 mL/kg IV rapidly**
- C. High-dose epinephrine, 0.1 mg/kg (0.1 mL/kg of 1:1,000 dilution), IO
- D. Amiodarone 5 mg/kg IO

Correct answer is B. The child presents in pulseless electrical activity (PEA) due to severe hypovolemia. PEA refers to any organized electrical activity observed on a 12-lead ECG or cardiac monitor in a patient with no detectable pulses. This definition specifically excludes VF, VT, and asystole. CPR and standard-dose epinephrine are indicated in the treatment of PEA while searching for and treating the cause of the condition. The α -adrenergic-mediated vasoconstriction of epinephrine increases aortic diastolic pressure and thus coronary perfusion pressure, a critical determinant of successful resuscitation. PEA may be reversible if it is identified early and treated appropriately. You can recall reversible causes of PEA in children using the H's and T's mnemonic. The 6 H's are **Hypovolemia**, **Hypoxia**, **Hydrogen ion (acidosis)**, **Hypo-/Hyperkalemia**, **Hypoglycemia**, and **Hypothermia**. The 5 T's are **Toxins**, **Tamponade (cardiac)**, **Tension pneumothorax**, **Thrombosis (coronary or pulmonary)**, and **Trauma**. The most likely reversible cause of PEA in this child is hypovolemia, so you should provide fluid boluses (20 mL/kg of isotonic crystalloid, repeated as needed). Unless a specific cause can be identified and treated, PEA will likely deteriorate to asystole.

Answer A is incorrect. Attempted defibrillation is indicated for the treatment of VF or pulseless VT but not for other forms of pulseless arrest, ie, asystole or PEA.

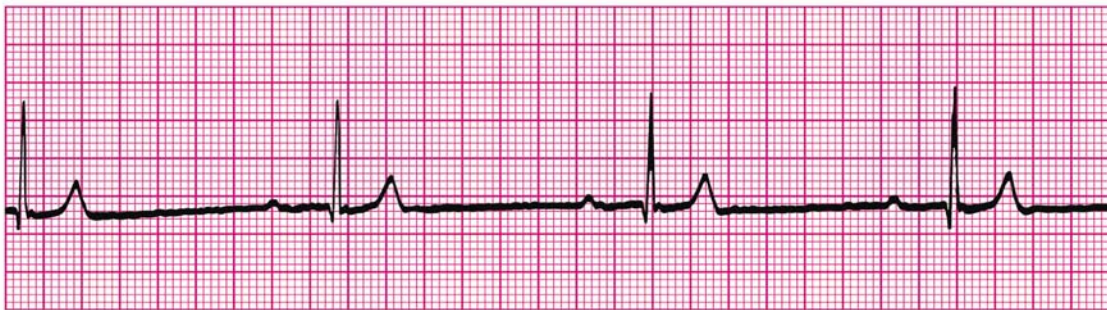Answer C is incorrect. Routine use of high-dose epinephrine is not indicated for the treatment of cardiac arrest in children. A prospective, randomized controlled trial of high-dose epinephrine for treatment of pediatric cardiac arrest failed to show survival benefit. This infant just received a standard dose of epinephrine and from the history the PEA is

more likely to respond to the correctable cause of hypovolemia than to epinephrine.

Answer D is incorrect. Amiodarone is indicated for the treatment of pulseless VT or VF refractory to defibrillation attempts and standard-dose epinephrine. Amiodarone is not indicated for the treatment of other forms of pulseless arrest, ie, asystole or PEA. Amiodarone may also be administered for tachycardias.

For further information: see the PALS Provider Manual Chapter 7: Recognition and Management of Cardiac Arrest, Chapter 9: Pharmacology, the PALS Course Guide Part 6: Cardiac Arrest, and Part 10: Pharmacology.

2. **General assessment of a 10-month-old male in the emergency department reveals a lethargic pale infant with slow respirations. You begin assisted ventilation with a bag-mask device using 100% oxygen. On primary assessment heart rate is 38/min, central pulses are weak but distal pulses cannot be palpated, blood pressure is 60/40 mm Hg, and capillary refill is 4 seconds. During your assessment a colleague places the child on a cardiac monitor and you observe the following rhythm:**



The rhythm remains unchanged despite ventilation with 100% oxygen. What are your next management steps?

- A. Administer adenosine 0.1 mg/kg rapid IV/IO and prepare for synchronized cardioversion
- B. Start chest compressions and give epinephrine 0.1 mg/kg (0.1 mL/kg of 1:1,000 dilution) IV/IO
- C. Start chest compressions and give epinephrine 0.01 mg/kg mL/kg of 1:10,000 dilution) IV/IO**
- D. Administer 20 mL/kg isotonic crystalloid and epinephrine 0.1 mg/kg mL/kg of 1:10,000 dilution) IV/IO

Correct answer is C. The rhythm on the monitor is sinus bradycardia with first-degree AV block. Bradycardia is characterized by a heart rate that is slower than normal for the patient's age. This infant's heart rate of 38/min is slower than a normal heart rate for a 10-month-old infant, which should be at least 75/min sleeping and 100/min awake. The important point for management is that the infant has persistent *symptomatic bradycardia* with a HR <60/min and poor perfusion and hypotension despite support of

oxygenation and ventilation. The next management steps should be initiation of chest compressions (rate 100/min) coordinated with assisted ventilations via bag-mask (compression-to-ventilation ratio of 15:2) and administration of standard-dose epinephrine (0.01 mg/kg or 0.1 mL/kg of 1:10,000 dilution). The CPR is needed because the infant's heart rate is insufficient to support perfusion and you are hoping to prevent progression to pulseless arrest. This infant does have first-degree AV block. Every QRS complex is preceded by a P wave and the PR interval is consistent but prolonged. If the infant does not respond to CPR and epinephrine, you can consider atropine and cardiac pacing. Also attempt to identify any reversible causes of the bradycardia.

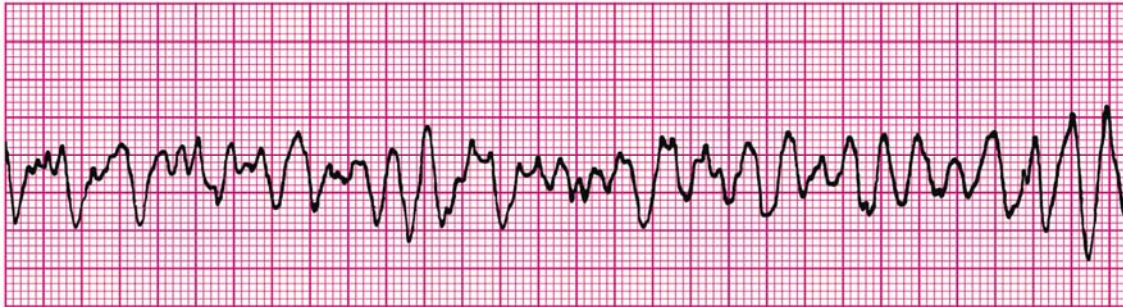
Answer A is incorrect. Adenosine and cardioversion are not indicated for the treatment of symptomatic bradycardia with pulses.

Answer B is incorrect. Although initiation of chest compressions is correct (because of heart rate <60/min with severe symptoms), high-dose epinephrine is not indicated for the treatment of symptomatic bradycardia with pulses. Use of high-dose epinephrine may be considered in special resuscitation circumstances (eg, calcium channel blocker poisoning and β -adrenergic blocker poisoning).

Answer D is incorrect. CPR and standard-dose epinephrine are indicated in the initial treatment of this infant with symptomatic bradycardia refractory to oxygenation and ventilation. Fluid resuscitation with isotonic crystalloid may be indicated as well, but it does not have priority over initiation of chest compressions because of heart rate <60/min).

For further information: see the PALS Provider Manual Chapter 6: Recognition and Management of Bradyarrhythmias and Tachyarrhythmias, Chapter 9: Pharmacology, the PALS Course Guide Part 7: Bradyarrhythmias and Tachyarrhythmias and Part 10: Pharmacology.

3. A 3-year-old unresponsive, apneic child is brought to the emergency department. EMS personnel report that the child became unresponsive as they arrived at the hospital. The child is receiving CPR, including bag-mask ventilation with 100% oxygen and chest compressions at a rate of 100/min. Compressions and ventilations are being coordinated at a ratio of 15:2. You confirm that apnea is present and that ventilation is producing bilateral breath sounds and chest expansion while a colleague confirms absent pulses. Cardiac monitor shows the following rhythm:



A biphasic manual defibrillator is present. You quickly use the crown-heel length of the child on a length-based, color-coded resuscitation tape to estimate the approximate weight as 15 kg. Which of the following therapies is most appropriate for this child at this time?

- A. Establish IV/IO access and administer amiodarone 5 mg/kg IV/IO
- B. Establish IV/IO access and administer lidocaine 1 mg/kg IV/IO
- C. Attempt defibrillation at 30 J, then resume CPR beginning with compressions**
- D. Establish IV/IO access and administer epinephrine 0.01 mg/kg (0.1 mL/kg of 1:10,000 dilution) IV/IO

Correct answer is C. The first therapy you should provide for VF or pulseless VT is an immediate attempt at defibrillation. The first "dose" for infants and children is 2 J/kg, followed by immediate CPR, beginning with compressions. If VF or pulseless VT persists after 2 minutes of CPR, you should attempt defibrillation with a dose of 4 J/kg, followed by immediate CPR. Your colleagues should try to establish IV/IO access to enable administration of epinephrine.

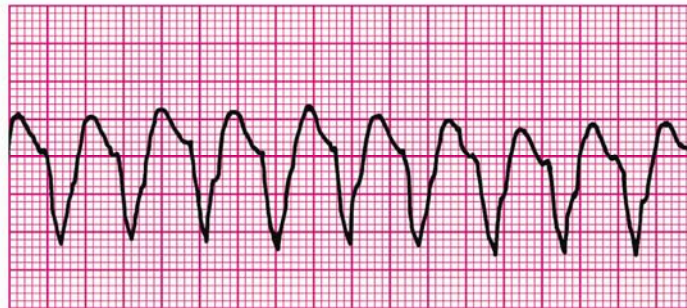
Answers A and B are incorrect. Although establishment of IV/IO access should be accomplished quickly, it should not delay the defibrillation attempt. You can wait to establish vascular access until after the delivery of the first shock. Administration of amiodarone or lidocaine is not recommended unless or until the VF/pulseless VT persists despite 2 to 3 attempts at defibrillation (2 J/kg, 4 J/kg 4 J/kg each separated by cycles of CPR) and a dose of epinephrine. Note that the epinephrine may be given if pulseless VT/VF persists after 1 shock and 2 minutes of CPR. However, there will be variability in the timing of the dose, based on speed of establishment of IV/IO access.

Answer D is incorrect. Although establishment of IV/IO access should be accomplished quickly, it should not delay the defibrillation attempt. You can wait to establish vascular

access until after the delivery of the first shock if needed. Epinephrine should be given when IV/IO access is established if VF/pulseless VT persists in the rhythm check after delivery of the first shock and 2 minutes of CPR.

For further information: see the PALS Provider Manual Chapter 7: Recognition and Management of Cardiac Arrest, Chapter 9: Pharmacology, the PALS Course Guide Part 6: Cardiac Arrest, and Part 10: Pharmacology.

4. **General assessment of a 10-year-old male shows him to be unresponsive. You shout for help, check breathing, find he is apneic, and give 2 breaths. After finding that he is pulseless, you begin cycles of compressions and ventilations with a compression rate of 100/min and compression-to-ventilation ratio of 30:2. A colleague arrives and places the child on a cardiac monitor, revealing the following rhythm:**



The two of you attempt defibrillation at 2 J/kg and give 2 minutes of CPR. The rhythm persists at the second rhythm check, at which point you attempt defibrillation using 4 J/kg. A third colleague establishes IO access and administers one dose of epinephrine 0.01 mg/kg (0.1 mL/kg of 1:10,000 dilution) during the compressions following the second shock. If VF or pulseless VT persists after 2 minutes of CPR, what is the *next* drug/dose to administer?

- A. Epinephrine 0.1 mg/kg (0.1 mL/kg of 1:1,000 dilution) IV
- B. Adenosine 0.1 mg/kg IV
- C. Amiodarone 5 mg/kg IV**
- D. Atropine 0.02 mg/kg IV

Correct answer is C. The patient's rhythm is pulseless VT. Amiodarone is indicated for the treatment of pulseless VT or VF refractory to defibrillation attempts and standard-dose epinephrine. Amiodarone slows AV conduction, prolongs the AV refractory period and QT interval, and slows ventricular conduction (widens the QRS).

Answer A is incorrect. Routine use of high-dose epinephrine (0.1 mg/kg or 0.1 mL/kg of 1:1,000 dilution) is not indicated for the treatment of VF or pulseless VT. High-dose epinephrine may be considered in special resuscitation circumstances (eg, calcium

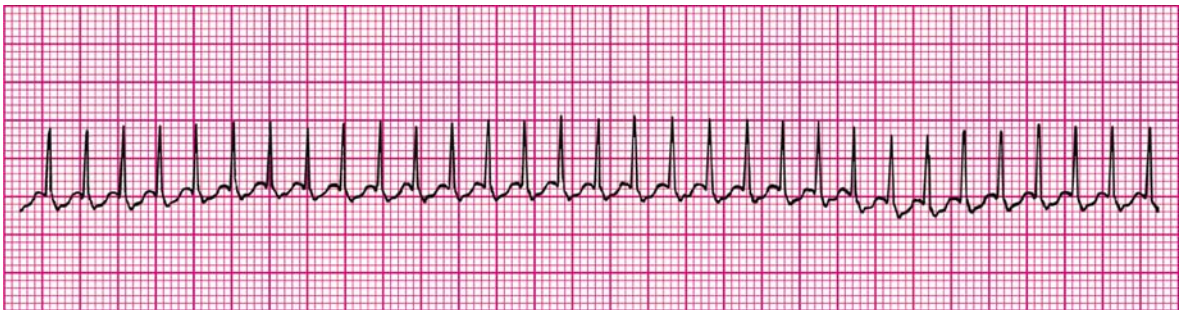
channel blocker poisoning and β -adrenergic blocker poisoning) that are unresponsive to standard-dose epinephrine.

Answer B is incorrect. Adenosine is indicated for the treatment of SVT. Although SVT with aberrant intraventricular conduction may produce a wide-complex tachycardia that would respond to adenosine, adenosine is not indicated for the treatment of *pulseless* wide-complex tachycardia.

Answer D is incorrect. Atropine is indicated for the treatment of symptomatic bradycardia with pulses due to increased vagal tone or primary AV block. Atropine is not indicated for pulseless arrest in children.

For further information: see the PALS Provider Manual Chapter 7: Recognition and Management of Cardiac Arrest, Chapter 9: Pharmacology, the PALS Course Guide Part 6: Cardiac Arrest, and Part 10: Pharmacology.

5. **A 1-year-old male is brought to the emergency department for evaluation of poor feeding, fussiness, and sweating. On general assessment he is lethargic but arousable and has labored breathing and a dusky color. Primary assessment reveals a respiratory rate of 68/min, heart rate 300/min that does not vary with activity or sleep, blood pressure 70/45 mm Hg, weak brachial pulses and absent radial pulses, capillary refill 6 seconds, SpO₂ 85% in room air, and good bilateral breath sounds. You administer high-flow oxygen and place the child on a cardiac monitor. You see the following rhythm with little beat-to-beat variability of the heart rate:**



Secondary assessment reveals no history of congenital heart disease. IV access has been established. Which of the following therapies is most appropriate for this infant?

- A. Make an appointment with a pediatric cardiologist for later in the week
- B. Adenosine 0.1 mg/kg IV rapidly; if adenosine is not immediately available, perform synchronized cardioversion**
- C. Perform immediate defibrillation without waiting for IV access
- D. Establish IV access and administer a fluid bolus of 20 mL/kg isotonic crystalloid

Correct answer is B. The infant has signs and symptoms of tachycardia with poor perfusion. The infant has SVT with a heart rate >220/min, narrow QRS complexes, no

variability in the heart rate, and no history consistent with a cause for a marked sinus tachycardia. Because the infant is unstable and an IV is in place, adenosine may be given if immediately available. If adenosine is not immediately available, synchronized cardioversion should be performed since this child has tachycardia with poor perfusion.

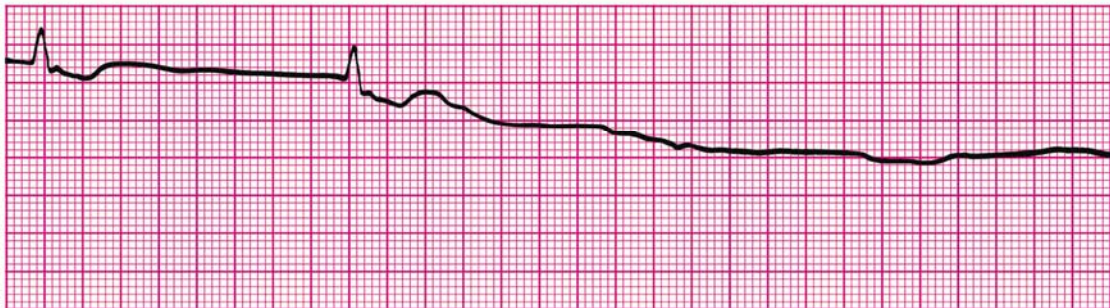
Answer A is incorrect. This child is unstable and immediate medical attention is required. Consultation with a pediatric cardiologist is appropriate, but you should not delay treatment.

Answer C is incorrect. Immediate or urgent defibrillation is not indicated for the treatment of tachycardia with a *pulse*. You should use synchronized cardioversion in this setting.

Answer D is incorrect. Administration of isotonic crystalloid will not treat and may worsen symptoms in a patient with SVT with poor perfusion. There is no history to suggest hypovolemia as the problem. Heart rates >220/min are less likely to be sinus in origin, so they are unlikely to be symptomatic of a problem such as hypovolemia.

For further information: see the PALS Provider Manual Chapter 6: Recognition and Management of Bradyarrhythmias and Tachyarrhythmias, and the PALS Course Guide Part 7: Bradyarrhythmias and Tachyarrhythmias.

-
6. A child becomes unresponsive in the emergency department and is not breathing. You provide ventilation with 100% oxygen. You are uncertain if a faint pulse is present with the following rhythm:



What is your *next* action?

- A. Begin high-quality chest compressions with ventilations
- B. Order transcutaneous pacing
- C. Start an IV and give atropine 0.01 mg/kg IV
- D. Start an IV and give epinephrine 0.01 mg/kg IV (0.1 mL/kg of 1:10,000 dilution)

Correct answer is A. The patient's rhythm strip shows asystole preceded by an agonal bradyarrhythmia. Asystole is cardiac standstill (ie, no ventricular depolarization). In addition to ventilation with 100% oxygen, the immediate treatment for asystole is CPR.

Rescuers should provide high-quality chest compressions (pushing hard, pushing fast at a rate of 100/min, allowing full chest recoil, and minimizing interruptions), and ventilations that produce visible chest rise.

Answer B is incorrect. Transcutaneous pacing may be indicated in the treatment of refractory bradyarrhythmias, but it is not indicated in the treatment of asystole.

Answer C is incorrect. Atropine is indicated for the treatment of symptomatic bradycardia with pulses due to increased vagal tone or primary AV block. Atropine is not indicated for the treatment of asystole in children.

Answer D is incorrect. Standard-dose epinephrine (0.01 mg/kg or 0.1 mL/kg of 1:10,000 dilution) is indicated in the treatment of asystole, but it does not have priority over CPR.

For further information: see the PALS Provider Manual Chapter 7: Recognition and Management of Cardiac Arrest, Chapter 9: Pharmacology, the PALS Course Guide Part 6: Cardiac Arrest, and Part 10: Pharmacology.

7. **You are preparing to use a manual defibrillator and paddles in the pediatric setting. When would it be most appropriate to use the smaller “pediatric” sized paddles for shock delivery?**
- A. To attempt synchronized cardioversion but not defibrillation
 - B. If the patient weighs less than approximately 25 kg or is less than 8 years of age
 - C. If the patient weighs less than approximately 10 kg or is less than 1 year of age**
 - D. Whenever you can compress the victim's chest using only the heel of one hand

Correct answer is C. The guidelines for defibrillation and cardioversion in infants and children recommend the use of the “infant” paddles for patients less than approximately 10 kg in weight or <1 year of age. For infants or children ≥ 10 kg in weight (or ≥ 1 year of age), the “adult” paddles should be used. The larger paddles reduce impedance and increase current flow. The paddle size is selected to provide the largest surface area of paddle or electrode contact with the chest wall without contact between the paddles or electrodes.

Answer A is incorrect. You should use the same paddle size for both defibrillation and synchronized cardioversion. There is no justification for using a smaller paddle size for cardioversion.

Answer B is incorrect. Use of the infant paddles for patients ≥ 10 kg in weight or ≥ 1 year of age may result in delivery of less current to the heart and increases the risk of local burns. To decrease chest impedance and increase current delivery to the heart, you should use the largest paddles that can be in complete contact with the chest wall while leaving about 3 cm between the paddles.

Answer D is incorrect. You compress the chest with the heel of one hand for children (approximately) 1 to 8 years of age. For the reasons noted above, the infant paddles are not appropriate for patients ≥ 10 kg in weight or ≥ 1 year of age.

For further information: see the PALS Provider Manual Chapter 7: Recognition and Management of Cardiac Arrest, Chapter 9: Pharmacology, and the PALS Course Guide Part 6: Cardiac Arrest.

8. **A 7-year-old boy is found unresponsive, apneic, and pulseless. CPR is ongoing. The child is intubated and vascular access is established. The ECG monitor reveals an organized rhythm, but a pulse check reveals no palpable pulses. Effective ventilations and compressions are resumed, and an initial IV dose of epinephrine is administered. Which of the following therapies should you perform next?**
- A. **Attempt to identify and treat reversible causes (using the H's and T's as a memory aid)**
 - B. Attempt defibrillation at 4 J/kg
 - C. Administer epinephrine 0.1 mg/kg IV (0.1 mL/kg of 1:1,000 dilution)
 - D. Administer synchronized cardioversion at 1 J/kg

Correct answer is A. The child presents in pulseless electrical activity (PEA). PEA refers to any organized electrical activity observed on a 12-lead ECG or cardiac monitor in a patient with no detectable pulses. Whenever a child with PEA or asystole does not respond to initial resuscitative efforts (support of airway, oxygenation, and ventilation, effective chest compressions, IV epinephrine), you should attempt to identify and treat potentially reversible causes of the cardiac arrest. This is especially true when PEA is present. These potentially reversible conditions can be recalled by the use of 6 H's: **Hypovolemia, Hypoxia, Hydrogen ion (acidosis), Hypo-/Hyperkalemia, Hypoglycemia,** and **Hypothermia**, and the 5 T's: **Toxins, Tamponade (cardiac), Tension pneumothorax, Thrombosis (coronary or pulmonary),** and **Trauma.**

Answer B is incorrect. Defibrillation is not recommended for treatment of PEA.

Answer C is incorrect. This dose is considered “high-dose” epinephrine. High-dose epinephrine is not recommended for the routine treatment of pulseless arrest. High-dose epinephrine may be considered for special resuscitation situations, such as calcium channel blocker poisoning and β -adrenergic blocker poisoning.

Answer D is incorrect. Synchronized cardioversion is not the treatment choice for PEA. Synchronized cardioversion is used to treat symptomatic tachyarrhythmias.

For further information: see the PALS Provider Manual Chapter 7: Recognition and Management of Cardiac Arrest, Chapter 9: Pharmacology, and the PALS Course Guide Part 6: Cardiac Arrest.

9. You are evaluating an irritable 6-year-old girl with mottled color. On primary assessment she is febrile (temperature 40°C [104°F]), and her extremities are cold (despite a warm ambient temperature in the room) with capillary refill of 5 seconds. Distal pulses are absent and central pulses are weak. Heart rate is 180/min, respiratory rate is 45/min, and blood pressure is 98/56 mm Hg. Which of the following most accurately describes the categorization of this child's condition using the terminology taught in the PALS Provider Course?
- A. Hypotensive shock associated with inadequate tissue perfusion
 - B. Hypotensive shock associated with inadequate tissue perfusion and significant hypotension
 - C. Compensated shock requiring no intervention
 - D. **Compensated shock associated with tachycardia and inadequate tissue perfusion**

Correct answer is D. Based on the clinical examination the child is in shock. It is *compensated* because her blood pressure is adequate (ie, systolic hypotension is *not* present) but signs of inadequate tissue and organ perfusion (eg, irritability, mottled color, cold extremities, absent distal pulses) *are* observed. To determine whether blood pressure is adequate in children aged 1 to 10 years, estimate the lower limit (5th percentile) of systolic blood pressure using the following formula: 70 mm Hg + (2 × age in years). A systolic blood pressure below the number yielded by this formula indicates hypotension. Using this formula, the lower limit of adequate systolic blood pressure for a 6-year-old child is 82 mm Hg. In this case the child's systolic blood pressure is 98 mm Hg, indicating adequate blood pressure. Thus if shock is present, it is *compensated* shock. You should assess the child for other objective evidence of shock, including altered responsiveness, decreased urine output, or evidence of lactic acidosis.

Answers A and B are incorrect. *Hypotensive* shock is characterized by the presence of systolic hypotension. In this case hypotensive shock would be present if the child's systolic blood pressure fell below 82 mm Hg.

Answer C is incorrect. Compensated shock should be treated promptly. Failure to treat compensated shock may result in deterioration to hypotensive shock or cardiac arrest.

For further information: see the PALS Provider Manual Chapter 4: Recognition of Shock, Chapter 5: Management of Shock, and the PALS Course Guide Part 9: Shock.

10. An 8-year-old child was struck by a car. He arrives in the emergency department alert, anxious, and in respiratory distress. His cervical spine is immobilized, and he is receiving a 10 L/min flow of 100% oxygen by nonrebreathing face mask. Primary assessment reveals respiratory rate 60/min, heart rate 150/min, systolic blood pressure 70 mm Hg, and SpO₂ 84% on supplementary oxygen. Breath sounds are absent over the right chest, and the trachea is deviated to the left. He has weak central pulses and absent distal pulses. Which of the following is the most appropriate immediate intervention for this child?
- A. Perform endotracheal intubation and call for a STAT chest x-ray
 - B. Provide bag-mask ventilation and call for a STAT chest x-ray
 - C. Establish IV access and administer a 20 mL/kg normal saline fluid bolus
 - D. **Perform needle decompression of the right chest and assist ventilation with a bag and mask if necessary**

Correct answer is D. This victim has signs of a tension pneumothorax: tachypnea with respiratory distress, absent breath sounds over the right chest, tracheal deviation to the left, SpO₂ of 84%, tachycardia, and poor perfusion with hypotension. You must evacuate the pneumothorax immediately to improve oxygenation and ventilation and to allow adequate venous return to the heart (and improved cardiac output). You should be prepared to assist ventilation with a bag and mask if needed. You should not await chest x-ray confirmation of the pneumothorax.

Answer A is incorrect. Needle decompression of the pneumothorax, not intubation, is the appropriate treatment for the tension pneumothorax. This child's airway appears to be patent, but his respiratory function is compromised. This compromise in respiratory function can be entirely explained by the tension pneumothorax. Treatment of a tension pneumothorax should not await chest x-ray confirmation.

Answer B is incorrect. Tension pneumothorax should be a clinical, not a radiographic, diagnosis. The tension pneumothorax should be evacuated as soon as the clinical diagnosis is made. Obtaining a chest x-ray will result in an unnecessary delay during which hypotension, hypoxemia, and ischemia can worsen, leading to progressive deterioration of cardiorespiratory function.

Answer C is incorrect. Establishing IV access is not as high a priority as stabilization of respiratory function. The cardiovascular compromise is probably secondary to the tension pneumothorax. Although fluid administration may be required, you should reevaluate the child's systemic perfusion *after* the tension pneumothorax is evacuated and you ensure that airway and breathing are adequate. Then you will assess circulation and treat shock if present.

For further information: see the PALS Provider Manual Chapter 4: Recognition of Shock, Chapter 5: Management of Shock, and the PALS Course Guide Part 9: Shock.

11. An 18-month-old child presents with a 1-week history of cough and runny nose. You perform a general assessment, which reveals a toddler responsive only to painful stimulation with slow respirations and diffuse cyanosis. You begin a primary assessment and find that the child's respiratory rate has fallen from 65/min to 10/min, severe inspiratory intercostal retractions are present, heart rate is 160/min, SpO₂ is 65% in room air, and capillary refill is less than 2 seconds. Which of the following is the most appropriate immediate treatment for this toddler?
- A. Establish vascular access and administer a 20 mL/kg bolus of isotonic crystalloid
 - B. Open the airway and provide positive-pressure ventilation using 100% oxygen and a bag-mask device**
 - C. Administer 100% oxygen by face mask, establish vascular access, and obtain a STAT chest x-ray
 - D. Administer 100% oxygen by face mask, obtain an arterial blood gas, and establish vascular access

Correct answer is B. This child demonstrates signs of overt respiratory failure with decreased responsiveness, severe inspiratory intercostal retractions, and an acute drop in respiratory rate from 65/min to 10/min. Immediate attention to the airway and ventilatory support with oxygen is indicated. You should interrupt your primary assessment to provide adequate support of oxygenation and ventilation.

Answer A is incorrect. Establishment of vascular access does not address the child's most immediate problem, ie, respiratory failure. The child has cyanosis, but it is most likely caused by respiratory failure and hypoxemia. No signs of poor systemic perfusion are present (capillary refill time is 2 seconds). The child's tachycardia is probably related to respiratory failure; the heart rate should normalize once the respiratory problem is treated.

Answers C and D are incorrect. The child requires more than supplementary oxygen to support respiratory status. Furthermore, oxygen delivered by face mask does not solve the problem of inadequate respiratory rate and excessive respiratory effort. Without adequate respiratory rate, supplementary oxygen delivered by face mask will not be transported into the child's lungs and circulatory system. This child's effort is significant but the child is tiring, and without immediate support of ventilation and oxygenation the child is at risk for progressive deterioration and respiratory arrest.

For further information: see the PALS Provider Manual Chapter 3: Recognition of Respiratory Distress and Failure, Chapter 4: Management of Respiratory Distress and Failure.

12. You are supervising another healthcare provider who is inserting an intraosseous (IO) needle into an infant's tibia. Which of the following signs should you tell the provider is the best indication of successful insertion of a needle into the bone marrow cavity?
- A. Pulsatile blood flow will be present in the needle hub
 - B. Fluids can be administered freely without local soft tissue swelling**
 - C. You are unable to aspirate any blood through the needle
 - D. Once inserted, the needle shaft of the needle moves easily in all directions within the bone

Correct answer is B. If fluids infuse easily and no soft tissue swelling develops near the site of insertion, the needle is probably correctly placed into the marrow cavity.

Answer A is incorrect. An IO needle is inserted into the bone marrow, which is a noncollapsible venous plexus. This venous plexus does not have pulsatile blood flow.

Answer C is incorrect. When the needle is inserted into the bone marrow cavity, the provider may be able to aspirate blood. Blood aspiration, however, is not always possible, and therefore the inability to aspirate blood does not necessarily indicate incorrect IO needle placement.

Answer D is incorrect. The IO needle will *not* move easily after insertion if it is correctly placed. It will typically be held in an upright position by bone.

For further information: see the PALS Provider Manual Chapter 4: Recognition of Shock, Chapter 5: Management of Shock, and the PALS Course Guide Part 9: Shock.

13. A pale and obtunded 3-year-old child with a history of diarrhea is brought to the hospital. Primary assessment reveals respiratory rate of 45/min with good breath sounds bilaterally. Heart rate is 150/min, blood pressure is 90/64 mm Hg, and SpO₂ is 92% in room air. Capillary refill is 5 seconds and peripheral pulses are weak. After placing the child on a nonrebreathing face mask (10 L/min flow) with 100% oxygen and obtaining vascular access, which of the following is the most appropriate immediate treatment for this child?
- A. Obtain a chest x-ray
 - B. Begin a maintenance crystalloid infusion
 - C. Administer a bolus of 20 mL/kg isotonic crystalloid**
 - D. Administer a dopamine infusion at 2 to 5 ug/kg per minute

Correct answer is C. This child has signs of *compensated* shock, including prolonged capillary refill, weak peripheral pulses, and tachycardia with a systolic blood pressure that is adequate for age. The shock is probably caused by hypovolemia secondary to diarrhea, so administration of an isotonic crystalloid fluid bolus is needed. A rapid bedside glucose test is also appropriate.

Answer A is incorrect. A chest x-ray is not indicated during the initial stabilization of the child. The child's respiratory rate is 45/min and breath sounds are clear. The child does have signs of compensated shock, and treatment for that should begin immediately.

Answer B is incorrect. To correct hypovolemic shock, you must give fluid boluses in increments of 20 mL/kg. Administration of maintenance fluids will not correct hypovolemic shock.

Answer D is incorrect. Administration of sufficient isotonic crystalloid is the most appropriate immediate treatment for this child's hypovolemic shock. A vasopressor like dopamine is unnecessary if resuscitation is successful with appropriate administration of fluid.

For further information: see the PALS Provider Manual Chapter 4: Recognition of Shock, Chapter 5: Management of Shock, and the PALS Course Guide Part 9: Shock.

14. You have just assisted with the elective endotracheal intubation of a child with respiratory failure and a perfusing rhythm. Which of the following provides the most reliable, prompt assessment of correct endotracheal tube placement in this child?

- A. Absence of audible breath sounds over the abdomen during positive-pressure ventilation
- B. Auscultation of breath sounds over the lateral chest bilaterally plus presence of mist in the endotracheal tube
- C. Confirmation of appropriate oxygen and carbon dioxide tensions on arterial blood gas analysis
- D. Clinical assessment of adequate bilateral breath sounds and chest expansion plus presence of exhaled CO₂ in a colorimetric detection device after delivery of 6 positive-pressure ventilations**

Correct answer is D. Both clinical assessment and use of an exhaled CO₂ device are needed for assessment of correct placement of an endotracheal tube because no single assessment technique is reliable under all conditions. Careful technique is required because the consequences of a misplaced or displaced tube can be fatal. Breath sounds and chest expansion should be adequate bilaterally. The presence of exhaled CO₂ after delivery of about 6 positive-pressure ventilations indicates tube placement in the trachea when a colorimetric exhaled CO₂ detection device is used in patients with a perfusing rhythm.

Answer A is incorrect. Studies in anesthetized children found that failure to hear breath sounds over the abdomen was not a reliable sign of correct endotracheal tube placement.

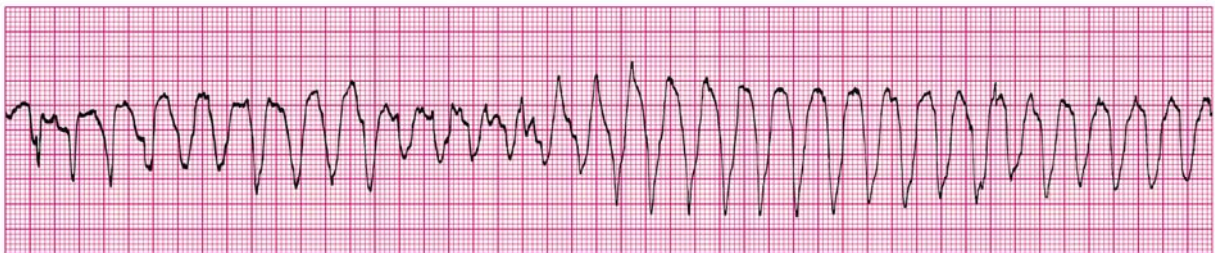
Answer B is incorrect. Inspiratory sounds heard over the lateral chest wall (and other parts of the chest) plus visible chest rise are all helpful clinical signs to assess proper endotracheal tube placement. Providers, however, should also use an exhaled CO₂ device to assess endotracheal tube position. If the child is >20 kg in weight and not

in cardiac arrest, an esophageal detector device can be used as an assessment device. Mist may be present in the endotracheal tube despite placement in the pharynx or esophagus instead of the trachea.

Answer C is incorrect. You should assess correct endotracheal tube placement clinically and with use of an exhaled CO₂ device. You should not rely on arterial blood gas analysis for assessment of correct endotracheal tube placement.

For further information: see the PALS Provider Manual Chapter 3: Recognition of Respiratory Distress and Failure, and Chapter 4: Management of Respiratory Distress and Failure.

15. **A 4-year-old male is in pulseless arrest in the pediatric intensive care unit. A code is in progress. As the on-call physician you quickly review his chart and find that his baseline corrected QT interval on a 12-lead ECG is prolonged. A glance at the monitor shows recurrent episodes of the following rhythm:**



The boy has received one dose of epinephrine 0.01 mg/kg (0.1 mL/kg of 1:10,000 dilution) but continues to demonstrate the rhythm illustrated above. If this rhythm persists at the next rhythm check, which medication would be *most* appropriate to administer at this time?

- A. Adenosine 0.1 mg/kg IV
- B. Epinephrine 0.1 mg/kg (0.1 mL/kg of 1:1,000 dilution) IV
- C. Lidocaine 1 mg/kg IV
- D. Magnesium sulfate 50 mg/kg IV**

Correct answer is D. The patient's rhythm is torsades de pointes ("twisting of the points"). This is a distinctive form of VT (polymorphic). It is characterized by QRS complexes that change in amplitude and polarity so that they appear to rotate around an isoelectric line. Characteristically torsades de pointes is associated with a markedly prolonged baseline QT interval (identified during sinus rhythm), and it may be caused by drug toxicity. The drug of choice for the treatment of torsades de pointes is magnesium sulfate at a dose of 25 to 50 mg/kg.

Answer A is incorrect. Adenosine is not indicated for the treatment of ventricular arrhythmias.

Answer B is incorrect. High-dose epinephrine (0.1 mg/kg or 0.1 mL/kg of 1:1,000

dilution) is not indicated for the treatment of torsades de pointes. Routine use of high-dose epinephrine may be considered in special resuscitation circumstances (eg, calcium channel blocker poisoning and β -adrenergic blocker poisoning).

Answer C is incorrect. Lidocaine is not indicated for the treatment of torsades de pointes. Lidocaine is a sodium channel blocker that decreases automaticity and suppresses ventricular arrhythmias. Current data, however, suggests that lidocaine is not as effective as amiodarone for the treatment of VF/pulseless VT. Extrapolation from an adult series suggests that lidocaine is not effective for torsades de pointes.

For further information: see the PALS Provider Manual Chapter 7: Recognition and Management of Cardiac Arrest, Chapter 9: Pharmacology, the PALS Course Guide Part 6: Cardiac Arrest, and Part 10: Pharmacology.

16. You are participating in the elective intubation of a 4-year-old child with respiratory failure. You must select the appropriate sized uncuffed endotracheal tube. You do not have a color-coded, length-based tape to use to estimate correct endotracheal tube size. Which of the following is the most appropriate estimated size uncuffed endotracheal tube for an average 4-year-old?

- A. 3-mm tube
- B. 4-mm tube
- C. **5-mm tube**
- D. 6-mm tube

Correct answer is C. To estimate the size of an uncuffed endotracheal tube for children 1 to 10 years of age, you can use either of the following 2 formulas (they will yield the same answer):

$$\text{Uncuffed ET tube size (mm internal diameter)} = \frac{(\text{Age in years} + 16)}{4}$$

$$\text{Uncuffed ET tube size (mm internal diameter)} = \frac{(\text{Age in years})}{4} + 4$$

Both of these formulas yield an estimated endotracheal tube size of 5 mm.

Answer A is incorrect. A 3-mm tube size is likely to be too small for a 4-year-old child and would likely result in a large air leak around the endotracheal tube. A 3-mm endotracheal tube would be appropriate for a newborn.

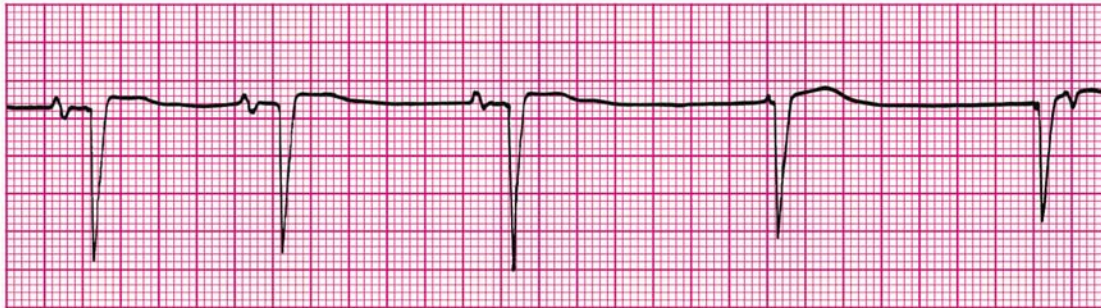
Answer B is incorrect. A 4-mm tube is likely to be too small for an average 4-year-old child. A 4-mm tube is the appropriate size for an infant approximately 6 to 12 months of age.

Answer D is incorrect. A 6-mm tube is likely to be much too large for an average 4-year-old child. A 6-mm tube is the appropriate size for a child approximately 8 years of age.

For further information: see the PALS Provider Manual Chapter 3: Recognition of Respiratory Distress and Failure, and Chapter 4: Management of Respiratory Distress and Failure.

-
17. You are caring for a 3-year-old with vomiting and diarrhea. You have established IV access. When you place an orogastric tube, the child begins gagging and continues to gag after the tube is placed. The child's color has deteriorated; pulses are palpable but faint and the child is now lethargic. The heart rate is variable (range 44/min to 62/min). You begin bag-mask ventilation with 100% oxygen. When the heart rate does not improve, you begin chest compressions.

The cardiac monitor shows



Which of the following would be the *most* appropriate therapy to consider next?

- A. Epinephrine 0.1 mg/kg (0.1 mL/kg of 1:1,000 dilution) IV
- B. Atropine 0.02 mg/kg IV**
- C. Attempt synchronized cardioversion at 0.5 J/kg
- D. Cardiology consult for transcutaneous pacing

Correct answer is B. Atropine would be the most appropriate drug to administer for symptomatic bradycardia unresponsive to adequate oxygenation and ventilation. You are providing chest compressions but a likely trigger for the bradycardia is vagal stimulation (expressed by the gag reflex) associated with insertion of the orogastric tube. Atropine is an appropriate drug to give for bradycardia due to vagal stimulation.

Answer A is incorrect. Although epinephrine can be given for symptomatic bradycardia, the correct dose to administer would be standard-dose epinephrine, not high-dose epinephrine.

Answer C is incorrect. Synchronized cardioversion is not the treatment choice for symptomatic bradycardia with pulses. Synchronized cardioversion is used to treat symptomatic tachyarrhythmias.

Answer D is incorrect. Although transcutaneous pacing may be indicated for the treatment of symptomatic bradycardia, you would not typically initiate this therapy for the treatment of vagally-mediated bradycardia unless the child failed to respond to atropine and epinephrine.

For further information: see the PALS Provider Manual Chapter 6: Recognition and Management of Bradyarrhythmias and Tachyarrhythmias, Chapter 9: Pharmacology, the PALS Course Guide Part 7: Bradyarrhythmias and Tachyarrhythmias and Part 10: Pharmacology.

18. You are transporting a 6-year-old endotracheally intubated patient who is receiving positive-pressure mechanical ventilation. The child begins to move his head and suddenly becomes cyanotic and bradycardic. SpO₂ is 65% with good pulse signal. You remove the child from the mechanical ventilator circuit and provide manual ventilation with a bag via the endotracheal tube. During manual ventilation with 100% oxygen, the child's color and heart rate improve slightly and his blood pressure remains adequate. Breath sounds and chest expansion are present and adequate on the right side, but they are consistently diminished on the left side. The trachea is not deviated, and the neck veins are not distended. A suction catheter passes easily beyond the tip of the endotracheal tube. Which of the following is the most likely cause of this child's acute deterioration?
- A. Tracheal tube displacement into the right main bronchus
 - B. Tracheal tube obstruction
 - C. Tension pneumothorax on the right side
 - D. Equipment failure

Correct answer is A. The child's movement has most likely displaced the endotracheal tube into the right main bronchus. The child's initial symptoms of cyanosis, bradycardia, and oxyhemoglobin desaturation are consistent with endotracheal tube displacement, tube obstruction, pneumothorax, or equipment failure, the elements of the DOPE mnemonic (ie, **D**isplacement of the tube from the trachea, **O**bstruction of the tube, **P**neumothorax, and **E**quipment failure). With manual ventilation producing adequate chest expansion and breath sounds on the right side, you have ruled out equipment failure and tube obstruction. Since there are good breath sounds and chest expansion on the right but not the left, tube displacement to the right main bronchus or a left pneumothorax would still be possible causes of deterioration. Because the child's head moved just before the deterioration and because there are no signs of tension pneumothorax, endotracheal tube displacement is most likely.

Answer B is incorrect. Endotracheal tube obstruction would likely cause a bilateral decrease in breath sounds that would not improve with manual ventilation. Furthermore, the patient would be difficult to ventilate with a manual device, and the suction catheter might not pass easily beyond the tip of the tube if there were an obstruction. If the obstruction were caused by thick mucus, particularly beyond the tip of the endotracheal tube, the catheter might pass readily despite the presence of an obstruction.

Answer C is incorrect. A pneumothorax on the *right* side would not be consistent with chest expansion and breath sounds that are adequate on the right side but diminished on the left side. Diminished breath sounds on one side can indicate the presence of a pneumothorax. A tension pneumothorax may cause tracheal midline shift or neck vein distention, but these are uncommon signs of tension pneumothorax in children and may not occur until late in the course if they are present. Nonetheless the signs and response

to manual ventilation in this patient make tube displacement into the right main bronchus much more likely than a right pneumothorax.

Answer D is incorrect. If equipment failure were the problem, the child would likely improve rapidly once he was removed from the mechanical ventilatory circuit and manual ventilation was provided.

For further information: see the PALS Provider Manual Chapter 3: Recognition of Respiratory Distress and Failure, and Chapter 4: Management of Respiratory Distress and Failure.

19. **A 3-year-old boy presents with multiple system trauma. The child was an unrestrained passenger in a motor vehicle crash. On primary assessment he is unresponsive to voice or painful stimulation. His respiratory rate is <6/min, heart rate is 170/min, systolic blood pressure is 60 mm Hg, capillary refill is 5 seconds, and SpO₂ is 75% in room air. Which of the following most accurately summarizes the first actions you should take to support this child?**
- A. Provide 100% oxygen by simple mask, stabilize the cervical spine, establish vascular access, and provide maintenance IV fluids
 - B. Provide 100% oxygen by simple mask and perform a head-to-toe survey to identify the extent of all injuries; begin an epinephrine infusion and titrate to maintain a systolic blood pressure of at least 76 mm Hg
 - C. Establish immediate vascular access, administer 20 mL/kg isotonic crystalloid, and reassess the patient; if the child's systemic perfusion does not improve, administer 10 to 20 mL/kg packed red blood cells
 - D. Open the airway (jaw-thrust technique) while stabilizing the cervical spine, administer positive-pressure ventilation with 100% oxygen, and establish immediate IV/IO access**

Correct answer is D. This child presents with multiple system trauma with evidence of shock, head injury, and depressed respirations. The first steps in management include opening the airway (preferred technique in trauma is jaw thrust) and clearing the airway while stabilizing the cervical spine, and assessment of breathing (inadequate in this case as demonstrated by respiratory rate of <6/min and SpO₂ of 75% in room air). This child needs immediate positive-pressure ventilation with 100% oxygen while maintaining cervical spine immobilization. Once the child's airway, oxygenation, and ventilation have been effectively supported, the next step in management is the assessment and support of the child's circulation. This child is hypotensive (ie, systolic blood pressure is <70 mm Hg + [2 × age in years]) with poor perfusion. You will need to rapidly establish vascular access (IV or IO) to administer a 20 mL/kg bolus of isotonic crystalloid. After fluid administration you should reassess the child.

Answer A is incorrect. The child's ventilation is inadequate (respiratory rate <6/min with evidence of hypoxemia) and requires immediate assisted ventilation with 100% oxygen. Administration of oxygen by face mask will not provide effective ventilation. As with other pediatric emergencies, the initial approach is support of airway and breathing with cervical spine immobilization; these interventions take priority over establishment of vascular access. Once vascular access is established, maintenance fluids are

insufficient for resuscitation of a child with hypotensive hypovolemic shock.

Answer B is incorrect. Airway and breathing should be supported with bag-mask ventilation (see above) during the initial assessment before the head-to-toe survey is performed. Epinephrine infusion is not indicated until after adequate volume resuscitation is provided.

Answer C is incorrect. Vascular access and volume resuscitation (with crystalloid and with blood products) are not the initial priorities. Although those actions will eventually be required, you must first open the airway and provide assisted ventilation with 100% oxygen while keeping the cervical spine immobilized. Then establishment of IV/IO access and fluid bolus administration will be appropriate.

For further information: see the PALS Provider Manual Chapter 3: Recognition of Respiratory Distress and Failure, and Chapter 4: Management of Respiratory Distress and Failure,